

doi: <http://dx.doi.org/10.11606/issn.1679-9836.v.94i1p1-5>

Medidas biométricas envolvendo a porção terminal do ducto torácico no nível cervical IV à esquerda: um estudo anatômico

Biometric measurements involving the terminal portion of the thoracic duct on left level IV: an anatomic study

Andressa Cristina Sposato Louzada¹, Soo Jin Lim¹, Alvaro Masahiro Yoshio¹, Vergilius José Furtado Araújo-Neto², Cesar Augusto Simões³, Leandro Luongo Matos⁴, Claudio Roberto Cernea⁵

Louzada ACS, Lim SJ, Yoshio AM, Araújo-Neto VJF, Simões CA, Matos LL, Cernea CR. Medidas biométricas envolvendo a porção terminal do ducto torácico no nível cervical IV à esquerda: um estudo anatômico / *Biometric measurements involving the terminal portion of the thoracic duct on left level IV: an anatomic study*. Rev Med (São Paulo). 2015 jan.-mar.;94(1):1-5.

RESUMO: INTRODUÇÃO: No esvaziamento cervical do nível IV à esquerda, a porção final do ducto torácico (DT) pode ser lesada, aumentando significativamente a morbimortalidade pós-operatória. O melhor tratamento é a prevenção. Contudo, não há disponível na literatura medidas biométricas que auxiliem a identificação da desembocadura do DT. MATERIAIS E MÉTODOS: a desembocadura do DT foi identificada e distâncias úteis foram medidas em 25 cadáveres não-formolizados. Análise estatística foi realizada para verificar associações. RESULTADOS: a desembocadura do DT ocorreu na confluência jugulo-subclávia (CJS – 60%), na veia jugular interna esquerda (VJIE – 36%) e na veia braquiocéfálica esquerda (4%). Uma associação estatisticamente significativa foi encontrada entre a desembocadura na confluência jugulo-subclávia e a distância entre a VJIE e o músculo omo-hioide (Medida #1). Indivíduos cujo DT desemboca na CJS apresentaram a Medida #1 com

mediana de 34.5±12.0mm, já os com desembocadura na VJIE apresentaram mediana de 22.3±8.7mm ($p=0.015$ – Student's *t*-test). A regressão logística demonstrou que para cada aumento de 10mm na Medida #1 há uma chance de 1.12x de encontrar a desembocadura do DT na CJS (OR=1.12; CI95%:1,01-1,25; $p=0.032$). Para essa Medida #1 estabeleceu-se um cut-off de 19mm como teste diagnóstico para prever a desembocadura do DT na CJS, com sensibilidade de 86.7% (CI95%:59.5-98.3%), especificidade de 55.6% (CI95%:21.2-86.3%), PPV de 76.5% (CI95%:50.1-93.2%), NPV de 71.4% (CI95%:25.8-97.2%) e ROC AUC de 79.3% (CI95%: 58.0-92.9%). CONCLUSÃO: este estudo anatômico demonstrou que o local de desembocadura do DT mais frequente é a CJS e que a Medida #1 é capaz de prever o local de desembocadura do DT.

DESCRIPTORIOS: Ducto torácico; Anatomia; Esvaziamento cervical; Cirurgia

1º lugar Prêmio Oswaldo Cruz - Área Cirúrgica e Prêmio Fundação Faculdade de Medicina no 33º COMU - Congresso Médico Universitário da FMUSP, SP, 31 de out. a 02 de nov. de 2014.

Instituição em que o estudo foi desenvolvido: Faculdade de Medicina da Universidade de São Paulo.

1. Acadêmicos de Medicina, Faculdade de Medicina da Universidade de São Paulo. E-mails: drelouzada@gmail.com; soojinlim91@gmail.com; alvaromy_yoshio@hotmail.com.
2. Acadêmico de medicina quando o estudo iniciou e atualmente é residente de cirurgia geral no Hospital das Clínicas da Faculdade de Medicina da Universidade de São Paulo. E-mail: vergiliusneto@gmail.com.
3. Médico Assistente, Departamento de Cirurgia de Cabeça e Pescoço do Hospital das Clínicas da Faculdade de Medicina da Universidade de São Paulo; Professor titular da Faculdade de Medicina da Universidade de Santo Amaro.
4. Professor livre-docente, Departamento de Cirurgia de Cabeça e Pescoço do Hospital das Clínicas da Faculdade de Medicina da Universidade de São Paulo; Médico assistente, Instituto do Câncer do Estado de São Paulo. E-mail: lmatos@amcham.com.br.
5. Professor livre-docente e professor afiliado, Departamento de Cirurgia de Cabeça e Pescoço do Hospital das Clínicas da Faculdade de Medicina da Universidade de São Paulo. E-mail: cerneamd@uol.com.br.

Endereço para correspondência: Andressa Cristina Sposato Louzada. Av. Paulista, 1636 – Cj. 209. CEP: 01310-200. São Paulo, SP. E-mail: drelouzada@gmail.com.

ABSTRACT: BACKGROUND: During a neck dissection involving the left IV level, the final segment of the thoracic duct (TD) may be injured, significantly increasing postoperative morbi-mortality. The best treatment is its prevention. However, there is a lack of helpful biometric measurements focusing on the TD termination in the literature. **MATERIALS AND METHODS:** The TD termination was identified and some helpful biometric measurements were obtained on 25 non-preserved cadavers. Statistical analysis was performed to analyze correlations. **RESULTS:** TD termination was found on the jugulo-subclavian junction (JSJ - 60%), on the left internal jugular vein (LIJV - 36%), and on the left brachiocephalic vein in 4%. A statistically significant association was found between TD termination on the JSJ and the distance between LIJV and omohyoid muscle (Measurement #1). Individuals with TD termination on the JSJ had median Measurement #1 of 34.5±12.0mm, compared with

median Measurement #1 of 22.3±8.7mm among individuals with TD termination on LIJV ($p=0.015$ – Student's *t*-test). The logistic regression showed for every 10mm increment of Measurement #1 there was 1.12x chance to find the TD termination on the JSJ (OR=1.12; CI95%:1,01-1,25; $p=0.032$). A 19mm cut-off was established for this distance as a diagnostic test to predict the TD termination on the JSJ, with sensitivity of 86.7% (CI95%:59.5-98.3%), specificity of 55.6% (CI95%:21.2-86.3%), PPV of 76.5% (CI95%:50.1-93.2%), NPV of 71.4% (CI95%:25.8-97.2%) and ROC AUC of 79.3% (CI95%:58.0-92.9%). **CONCLUSION:** This anatomic study demonstrated the most frequent TD termination was on JSJ and Measurement #1 is able to predict the localization of TD termination.

KEYWORDS: Thoracic duct; Anatomy; Neck dissection; Surgery

BACKGROUND

The thoracic duct collects lymph from the inferior limbs, the abdomen, the left hemi-thorax, the left arm and the left side of the head and neck.

Besides carrying lymph with fat, fat-soluble vitamins, electrolytes and lymphocytes, the thoracic duct is physiologically the main route for returning several important extravascular proteins into the circulation, including enzymes^{1,2}.

During a neck dissection involving level IV on the left side, there is a risk of injury of this important lymphatic vessel at its final segment, before entering the venous system. Albeit infrequent, being reported in 1-3% of the cases³⁻¹³, this complication may bring significant postoperative morbidity causing a prolonged time of hospitalization. This represents higher therapy-related costs and even higher risks for the patient's health.

An injury to the thoracic duct produces a chylous fistula which leads to chyle leak, an extremely serious metabolic complication. Chyle leak is associated with loss of tissue fluid, such as electrolyte imbalance, hypovolaemia, hypoproteinemia, periferic edema, lymphopenia, immunosuppression¹⁴ and coagulopathy. Added to that, the lymph infiltration and its subsequent dissection of adjacent structures may affect the surgical wound, causing dehiscence and secondary infection of this site¹⁵. If the chyle accumulates in the pleural cavity, there may be also a significant impairment of the oxygenation resulting in cyanosis and dyspnea^{1,2}.

The thoracic duct may present some anatomic variations:

- Not crossing to the left side of the body at the T4 level, therefore having its final segment on the level IV on the right side rather than on the left side, which happens in less than 25% of the cases^{1,16,17};
- Duplicating or triplicating at the level of the thoracic vertebrae, thus being present bilaterally^{1,18-21,23};
- Draining into places other than the confluence between

the left internal jugular vein and the left subclavian vein, the most frequent drainage area. It has been reported that the thoracic duct may drain into the left subclavian vein^{10,17,18,20,21}; the left internal jugular vein^{1,10,17,21,22}; the brachycephalic vein^{1,17,21}; the left vertebral vein^{1,21}; right venous system^{1,16-18,20,21}; azygous vein²¹; transverse cervical vein¹⁷ or the inferior vena cava^{19,21}.

The chyle fistula is a severe neck dissection complication and that the best treatment is its prevention. In addition, there is a combination of wide anatomic variations of the final segment of the thoracic duct and a lack of helpful biometric measurements focusing on the point of entrance of the thoracic duct into the venous system available in the literature. Therefore, this anatomic study was designed to determine the point of entrance of the thoracic duct in the venous system, as well as to evaluate some biometric measurements on the IV level, in a series of non-preserved cadavers, which could help the surgeon to predict the site of the thoracic duct's termination.

METHODS

Anatomic Study

A prospective non-randomized anatomic study was performed on twenty five non-preserved cadavers that underwent necropsy. The sample comprised 64% male, 56% caucasian, aged 71 ± 15.3 years old, with median weight 57.3 ± 12.4 Kg, median height 1.65 ± 0.1 m and median BMI 21.3 ± 4.9 Kg/m².

A wide cervico-thoracic incision was performed on each cadaver, from one deltoid muscle to the other, 0.5 to 1 centimeter below the collar bones in order to prevent visible scars in their necks. Following the incision, the cutaneous flap was cranially dissected up to the hyoid, always as close as possible to the subcutaneous cellular tissue.

The left omohyoid muscle and the left internal jugular vein were then identified. Subsequently the course

of the left internal jugular vein until its confluence with the left subclavian vein was identified. From that, the brachiocephalic and innominate veins were also identified. Finally, the thoracic duct was searched and its localization was confirmed using the abdominal compression maneuver¹³. In this study, the thoracic duct was always found in the left side of the body. So there was no need to dissect the right side.

Using a pachymeter the following biometric measurements were then obtained: 1. Distance between the end of the thoracic duct and the intersection between the left internal jugular vein and the omohyoid muscle; 2. Distance between the end of the thoracic duct and the left internal jugular vein; 3. Distance between the end of the thoracic duct and the left subclavian vein; 4. Distance between the end of the thoracic duct and the end of the left brachiocephalic vein. The measurements were always obtained by two investigators. If both agreed, the measurement was then registered. If there was any disagreement, the distance was double checked, corrected and then registered.

Statistical Analysis

The values of the qualitative variables were described using absolute and relative frequencies. Kolmogorov-Smirnov test was performed to determine the distribution of the quantitative variables and the parametric ones were described using mean and standard deviation.

Student *t* test was performed for the parametrical quantitative data comparison as well as for the qualitative data comparison. For the non-parametric quantitative variables the data comparison was done using the Mann-Whitney U test.

To calculate risk a logistic regression model was performed to determine *odds ratio* (OR) and a confidence interval of 95% (CI 95%).

The Receiver Operating Characteristic curve was performed to validate the diagnosis tests and to determine the cut offs.

All these statistic analysis were done using the

statistical software SPSS® version 17.0 (SPSS® Inc; Illinois, USA) and a significance level of 5% was adopted for all comparisons ($p \leq 0.05$).

RESULTS

The termination of the thoracic duct occurred exactly on the confluence between the left internal jugular vein and the left subclavian vein in 60% of the individuals, directly on the left internal jugular vein in 36%, and on the middle third of the left brachiocephalic vein in 4%. Since there was only one case of termination of the thoracic duct on the left vertebral vein, the comparisons made in this study were only between the termination of the thoracic duct exactly on the confluence between the left internal jugular vein and the left subclavian vein *versus* directly on the left internal jugular vein.

Concerning the biometric measurements, we observed:

- 1) From 12 to 61mm (mean of 31.2 ± 13.5 mm), for the distance between the end of the thoracic duct and the intersection between the left internal jugular vein and the omohyoid muscle;
- 2) From 0 to 28mm (mean of 1.1 ± 5.6 mm) for the distance between the end of the thoracic duct and the left internal jugular vein;
- 3) From 0 to 16mm (mean of 3.6 ± 5.2 mm) for the distance between the end of the thoracic duct and the left subclavian vein;
- 4) From 0 to 19mm (mean of 10.7 ± 8.1 mm) for the distance between the end of the thoracic duct and the middle third of the left brachiocephalic vein.

In this study, no statistically significant association was found between the termination of the thoracic duct and the following parameters: gender, age, body mass index, height and weight.

Within the biometric measurements, the analysis showed a statistically significant association only regarding the distance between the intersection between the left internal jugular vein and the omohyoid muscle and the end of the thoracic duct on the confluence between the left internal jugular vein and the left subclavian vein (Table 1).

Table 1. Comparison between the biometric measurements and the end of the thoracic duct

Parameters	Junction between LIJV and LSCV	Exactly on the LIJV	p
Weight (kg)	60,0 ± 10,8	55,1 ± 13,6	0,340*
Height (m)	1,7 ± 0,1	1,6 ± 0,1	0,377*
BMI (kg/m ²)	21,8 ± 3,5	21,3 ± 6,2	0,801*
Age	70,8 ± 14,0	69,1 ± 18,3	0,801*
Distance between the end of the thoracic duct and the left internal jugular vein	0,0 ± 0,0	0,0 ± 0,0	1,0000**
Distance between the end of the thoracic duct and the left subclavian vein	0,0 ± 0,0	8,7 ± 4,3	<0,0001**
Distance between the end of the thoracic duct and the intersection between the left internal jugular vein and the omohyoid muscle	34,5 ± 12,0	22,3 ± 8,7	0,015*
Distance between the end of the thoracic duct and the middle third of the left brachiocephalic vein	4,8 ± 9,5	12,0 ± 2,8	0,373*
Distance between the end of the thoracic duct and the lower edge of the clavicle	16,3 ± 3,2	17,5 ± 7,7	0,597

* *t* Student test; ** Mann-Whitney test.

Individuals with this anatomic configuration had mean Measurement #1 of 34.5 ± 12.0 mm, compared with the mean Measurement #1 among individuals with thoracic duct termination on left internal jugular vein of 22.3 ± 8.7 mm ($p=0.015$ – Student *t* test). With this result, a logistic regression was performed, showing that for every 10 mm increment concerning the distance between the confluence between the left internal jugular vein and the left subclavian vein and the intersection of the left internal jugular vein and the omohyoid muscle there was a chance of 1.12 times to find the termination of the thoracic duct on the left jugular-subclavian junction (OR=1.12; CI95%: 1,01-1,25; $p=0.032$). Similarly, in the present series a cut-off value of 19 mm was established for this distance as a diagnostic test to predict the termination of the thoracic duct on the junction of the left internal jugular vein and left subclavian vein, with sensitivity of 86.7% (CI95%: 59.5-98.3%), specificity of 55.6% (CI95%: 21.2-86.3%), positive predictive value of 76.5% (CI95%: 50.1-93.2%), negative predictive value of 71.4% (CI95%: 25.8-97.2%) and area under the ROC curve of 79.3% (CI95%: 58.0-92.9%) as shown in Figure 1.

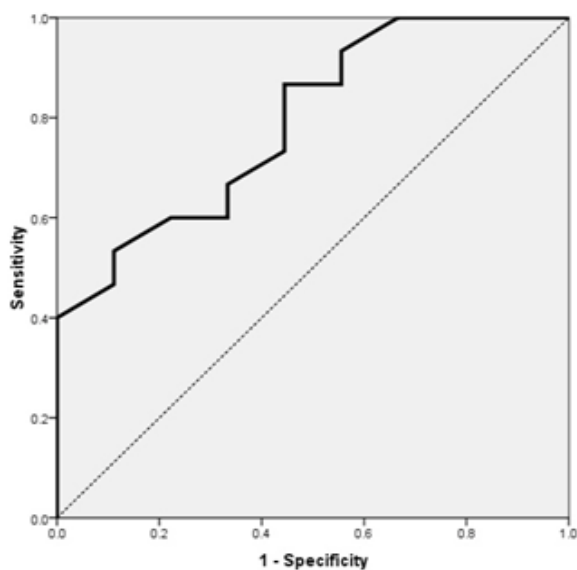


Figure 1. ROC curve as a diagnostic test to predict the termination of the thoracic duct on the confluence between the left internal jugular vein and left subclavian vein based on the distance between this confluence and the intersection of the left internal jugular vein and the omohyoid muscle – Area under the ROC curve: 0.793

REFERENCES

1. Bessone LN, Ferguson TB, Burford TH. Chylothorax. *An Thorac Surg.* 1971;12(5):527-50.
2. Vaz MAC, Fernandes PP. Quilotórax. *J Bras Pneumol.* 2006;32(supl 4):S197-S203. Disponível em: <http://www.scielo.br/pdf/jbpneu/v32s4/31838.pdf>.
3. Langford RJ, Daudia AT, Malins TJ. A morphological study

DISCUSSION

This anatomic study demonstrated that the most frequent termination of the thoracic duct was the junction of the left internal jugular vein and the left subclavian vein.

In addition, an important biometric measurement, the distance between this junction and the intersection between the left internal jugular vein and the omohyoid muscle, which is easily obtained during a neck dissection including the left level IV, is able to predict the localization of thoracic duct termination. That is, the wider this distance, the more likely it is for the thoracic duct to terminate exactly on the confluence between the left internal jugular vein and the left subclavian vein, as there is a chance of 1.12 times to find the termination of the thoracic duct on this confluence for every 10 mm increment concerning the distance of interest (OR=1.12; CI95%: 1,01-1,25; $p=0.032$). Therefore, this finding has a practical value in order to minimize the chance for a potential chyle leak during or after a neck dissection.

ETHICS

The authors declare no conflict of interest and all the cadavers were treated with the highest respect.

STUDY LIMITATIONS

In this observational study, no sample size calculation was performed since there is no similar study in the literature. Nevertheless the main finding of the study – the use of the distance between the junction the left subclavian and left internal jugular veins and the intersection of the left internal jugular vein and the omohyoid muscle to predict the termination of the thoracic duct – was presented as statistically significant after being calculated as two-tailed, with a confidence interval of 95% and a significance level of 5%. Therefore, the sample size of twenty-five cadavers was enough to determine this measurement as a truly predictor.

Moreover, since this is a non-randomized study performed on non-preserved cadavers that died of natural causes, the sample was not representative of the population. This might be the reason no statistically significant association was found between the termination of the thoracic duct and gender, age, body mass index, height or weight.

of the thoracic duct at the jugulo-subclavian junction. *J Craniomaxillofac Surg.* 1999;27(2):100-4. doi: 10.1016/S1010-5182(99)80021-3.

4. Dedivitis RA, Guimarães AV, Pfuetszenreiter Jr EG, Castro MAF. Complicações dos esvaziamentos cervicais. *Braz J Otorhinolaringol.* 2011;77(1):65-9. <http://dx.doi.org/10.1590/S1808-86942011000100011>.

5. Priego Jiménez P, Collado Guirao MV, Rojo Blanco R, Grajal Marino R, Rodríguez Velasco G, García Villanueva A. Chyle fistula in right cervical area after thyroid surgery. *Clin Transl Oncol*. 2008;10(9):593-6. doi: 10.1007/s12094-008-0257-4.
6. Raguse JD, Pfitzmann R, Bier J, Klein M. Lower-extremity lymphedema following neck dissection--an uncommon complication after cervical ligation of the thoracic duct. *Oral Oncol*. 2007;43(8):835-7. doi: 10.1016/j.oraloncology.2007.01.017.
7. van Goor AT, Kröger R, Klomp HM, de Jong MA, van den Brekel MW, Balm AJ. Introduction of lymphangiography and percutaneous embolization of the thoracic duct in a stepwise approach to the management of chylous fistulas. *Head Neck*. 2007;29(11):1017-23. doi: 10.1002/hed.20624.
8. de Gier HH, Balm AJ, Bruning PF, Gregor RT, Hilgers FJ. Systematic approach to the treatment of chylous leakage after neck dissection. *Head Neck*. 1996;18(4):347-51. doi: 10.1002/(SICI)1097-0347(199607/08)18:4<347::AID-HED6>3.0.CO;2-Y.
9. Spiro JD, Spiro RH, Strong EW. The management of chyle fistula. *Laryngoscope*. 1990;100(7):771-4. doi: 10.1002/lary.23216.
10. Cernea CR, Hojaij FC, Carlucci D Jr, Tavares MR, Araújo-Filho VJ, Michaluart P Jr, Montenegro FLM, Silva-Filho GB, Brandão LG. Abdominal compression: a new intraoperative maneuver to detect chyle fistulas during left neck dissections that include level IV. *Head Neck*. 2011;34(11):1570-3. doi: 10.1002/hed.21956.
11. Thawley SE. "How I do it" - head and neck. A targeted problem and its solution. Chylous fistula prevention and management. *Laryngoscope*. 1980;90(3):522-5.
12. Nussenbaum B, Liu JH, Sinard RJ. Systematic management of chyle fistula: the Southwestern experience and review of the literature. *Otolaryngol Head Neck Surg*. 2000;122(1):31-8. doi: 10.1016/S0194-5998(00)70140-9.
13. Jortay A, Bisschop P. Bilateral chylothorax after left radical neck dissection. *Acta Otorhinolaryngol Belg*. 2001;55(4):285-9.
14. Nowak K, Wierzbicka M, Szyfter W. Chylous leakage--rare but still dangerous complication after neck surgery. *Otolaryngol Pol*. 2011;65(2):128-31. doi: 10.1016/S0030-6657(11)70642-4.
15. Lehn CN, Walder F. Complications of neck dissections. *Rev Bras Cir Cabeça Pescoço*. 2003;32(3).
16. Peña E, Zuñiga J. Una variación anatómica: la desembocadura aberrante del conducto torácico. *Biomedica*. 2009;29(2):204-8. Available from: http://www.scielo.org.co/scielo.php?script=sci_arttext&pid=S0120-41572009000200005&lng=en&nrm=iso.
17. Kinnaert P. Anatomical variations of the cervical portion of the thoracic duct in man. *J Anat*. 1973;115(Pt 1):45-52. Available from: <http://www.ncbi.nlm.nih.gov/pmc/articles/PMC1271525/pdf/janat00312-0049.pdf>.
18. Seeger M, Bewig, Gunther R, Schafmayer C, Vollnberg B, Rubin D, Hoell C, Schreiber S, Fölsch UR, Hampe J. Terminal part of thoracic duct: high-resolution US imaging. *Radiology*. 2009;252(3):897-904. doi: <http://dx.doi.org/10.1148/radiol.2531082036>.
19. Anu VR, Rajalakshmi R, Latha VP, Mangala K. A rare lymphatic-venous communication associated with duplication of thoracic duct. *Int J Morphol*. 2006;24(2):155-8. <http://dx.doi.org/10.4067/S0717-95022006000300005>.
20. Marques SRB, Lins EM, Marchetti F, Sohsten WV. Visualização linfocintigráfica da desembocadura do ducto torácico. *J Vasc Bras*. 2005;4(4): <http://dx.doi.org/10.1590/S1677-54492005000400009>.
21. Bergman RA, Afifi AK, Miyauchi R. Lymphatics: thoracic duct and cisterna chyli. *Illustrated Encyclopedia of Human Anatomic Variation: Opus II: Cardiovascular System: Listing of the Cardiovascular System By Region*. Available from: <http://www.anatomyatlases.org/AnatomicVariants/Cardiovascular/Directory/Region/ArteriesLymphatics.shtml>.
22. Zorzetto NL, Ripari W, De Freitas V, Seullner G. Anatomical observations on the ending of the human thoracic duct. *J Morphol*. 1977;153(3):363-9.
23. Solis JH, Sánchez C, Gutiérrez R. Variantes anatómicas del conducto torácico. *Angiología*. 1984;36:289-92.