

Idiopathic sialadenosis involving parotid and submandibular glands: a case report

• **Norberto N. Sugaya** Department of Stomatology, School of Dentistry, University of São Paulo, SP, Brazil • **Juliana Seo** Department of Stomatology, School of Dentistry, University of São Paulo, SP, Brazil • **Silvio K. Hirota** Department of Stomatology, School of Dentistry, University of São Paulo, SP, Brazil • **Andre C. Rocha** Clinical Hospital, School of Medicine, Division of Dentistry, University of São Paulo, SP, Brazil • **Dante A. Migliari** Department of Stomatology, School of Dentistry, University of São Paulo, SP, Brazil

ABSTRACT | This article reports a case in which an adult black male patient was diagnosed as having sialadenosis of idiopathic type, since computed tomography, clinical, and laboratory examinations did not disclose any other abnormalities that could be associated with the glandular swelling observed in the patient. As this condition is quite harmless, requiring no intervention, unless for aesthetic reason, the patient was dismissed, being monitored sporadically. But after 8 months since the first consultation the patient was diagnosed as having an advanced esophageal squamous cell carcinoma, and eventually died of this disease. Therefore, this report raises the question whether there was any relation with the sialadenosis and the esophageal carcinoma. This question is very speculative, but it stands as a notice for clinicians in future cases of idiopathic sialadenosis to evaluate the patient for an underlying malignant disease.

DESCRIPTORS | Parotid Gland; Pathology; Salivary Glands; Salivary Gland Diseases; Sialadenosis.

RESUMO | **Sialoadenose do tipo idiopático envolvendo as glândulas parótida e submandibular: relato de caso** • Este relato descreve o caso de um paciente adulto negro diagnosticado com uma sialoadenose do tipo idiopático, uma vez que exames clínicos, de tomografia computadorizada e testes laboratoriais não revelaram qualquer outra anormalidade que pudesse ser associada ao aumento de volume glandular por ele apresentado. Considerando que essa condição é bastante benigna, não requerendo qualquer outra intervenção exceto por razões estéticas, o paciente foi dispensado e orientado a retornar para controles esporádicos. Entretanto, oito meses após sua consulta inicial, o paciente recebeu um diagnóstico de carcinoma de células escamosas avançado no esôfago, que o levou a óbito. Esse relato, então, levantou o questionamento de alguma relação entre a sialoadenose e o carcinoma esofágico. Essa questão é obviamente especulativa, mas permanece como um aviso aos clínicos para, em futuros casos de sialoadenose idiopática, avaliar o paciente para uma doença maligna subjacente.

DESCRITORES | Glândula Parótida; Patologia; Glândulas Salivares; Doenças das Glândulas Salivares; Sialoadenose.

CORRESPONDING AUTHOR | • **Norberto N. Sugaya** Department of Stomatology, School of Dentistry, University of São Paulo • **Av. Professor Lineu Prestes, 2227** São Paulo, SP, Brazil • **05508-000** E-mail: nnsugaya@usp.br

• Received Jan 14, 2015 • Accepted Mar 5, 2015
• DOI <http://dx.doi.org/10.11606/issn.2357-8041.cldr.2016.10854>

INTRODUCTION

Sialadenosis has been defined as a persistent, soft, and painless non-inflammatory and non-neoplastic disease of the salivary gland, usually involving the parotid glands, and less frequently the submandibular glands.¹ The disease occurs more frequently in adults, affecting male and female in equal frequency.^{1,2}

The etiology of sialadenosis is unknown; however, the reports have described this condition in association with systemic diseases such as diabetes mellitus, alcoholism, chronic malnutrition, antihypertensive therapy, bulimia, and HIV infection.¹⁻⁶

Diagnosis is based mainly on the clinical findings.² Ultrasound and computed tomography are very useful tools not only to confirm a clinical diagnosis of sialadenosis, but also to rule out other diseases, specifically neoplasias.⁵⁻⁷ Fine needle aspiration biopsy may be useful in some cases to differentiate an inflammatory mass from a neoplasia.⁸ The aim of this report is to show a case of sialadenosis of unknown cause, with a subtle speculation whether this condition could possibly have been a prodromic sign of an underlying esophagus carcinoma in advanced stage.

CASE REPORT

A 48-year-old black male was referred to our clinic for a diagnosis of a bilateral, painless swelling of the parotid and submandibular glands with 6-month duration (Figures 1A and B). The swollen areas were soft on palpation. The patient was a smoker of 20 cigarettes/day for 30 years, but not a habitual alcohol drinker. He was not taking any medication nor suffering of any systemic conditions. He had undergone a treatment for pneumonia 3 years before. Oral examination showed normal mucosa; both the parotid and submandibular glands were milking normally. The measuring of resting whole saliva flow rate was 0.6 mL/min,

indicating a normal output of saliva. Neck palpation revealed no sign of enlargement of the lymph nodes.

A diagnosis of sialadenosis was made and the patient underwent a laboratory examination in order to disclose any possible underlying disease. The exams included complete blood count, blood glucose level, liver function tests, and thyroid hormones. The results of all these tests were within normal limits. The patient was also tested for HIV infection, which was negative.

Although no signs of either a neoplasia or an inflammatory process occurring inside the salivary glands, a biopsy of minor salivary gland of the labial mucosa was provided. Histologic examination revealed normal arrangement of the glandular tissues. Further examination using computed tomography showed enlargement of the parotid glands. No intraglandular lesions or calcification were detected (Figure 1C).

Since nothing was found regarding the patient's general health, and considering that no treatment would be necessary for his condition, he was placed on periodic clinical evaluation under the clinical diagnosis of idiopathic sialadenosis. However, after 8 months he sought a medical consultation complaining of dysphagia. He was then submitted to an upper digestive tract endoscopy, which revealed an obstructive lesion on the esophageal tract. The histopathologic diagnosis was an invasive squamous cell carcinoma. The patient underwent surgical treatment but died 3 months later due to the disease.

DISCUSSION

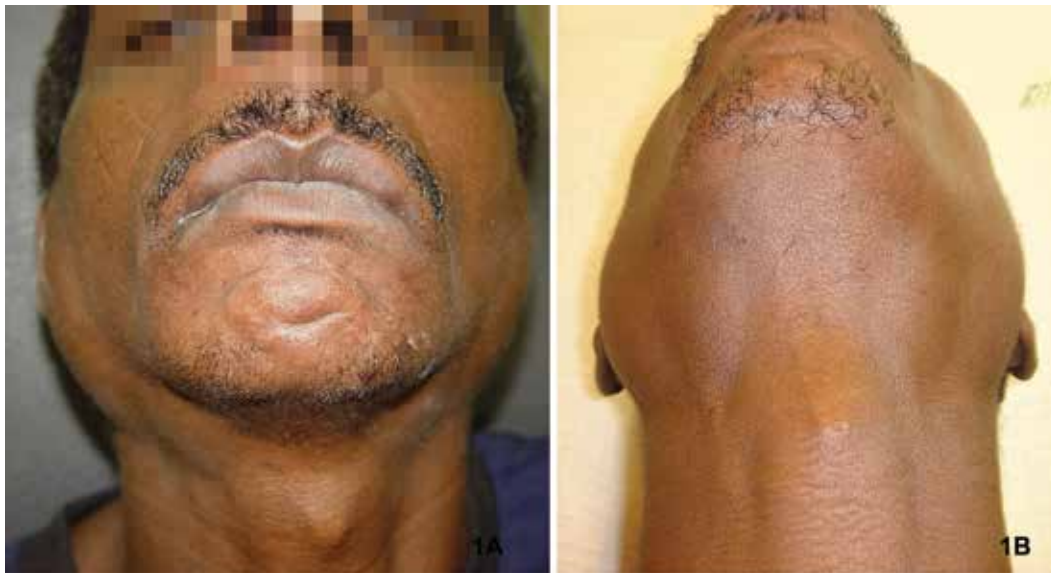Bilateral salivary gland swelling may reflect an autoimmune disease, viral infection, or a systemic condition. A complete diagnosis usually requires clinical, laboratory, and radiological investigations.^{2,9} In this case, the clinical evaluation ruled out both autoimmune and infective disease. Laboratory

investigation showed all exams within normal limits; blood test for HIV was negative. Computed tomography showed only enlargement of both parotid glands without any intraglandular lesion. Based on the radiography, clinical, and laboratory examinations, the final diagnosis was an idiopathic sialadenosis.

In this case, the use of needle-aspiration biopsy as an additional resource for a diagnosis of sialadenosis was deemed unnecessary since the clinical examination, coupled with laboratory investigation

and computed tomography analysis, did not show signs of inflammation on the glandular parenchyma, presence of intraglandular mass or nodules, or involvement of any systemic disease.

Sialadenosis usually does not require treatment, unless for aesthetic reasons, in which a total or partial parotidectomy remains the main treatment.^{1,5} In this case, no treatment was thought to be necessary. Therefore, the patient was monthly monitored by clinical examinations.



Figures 1A and B | Diffuse, bilateral swelling of the parotid and submandibular glands. There were no inflammatory signs; the swollen areas were soft on palpation.

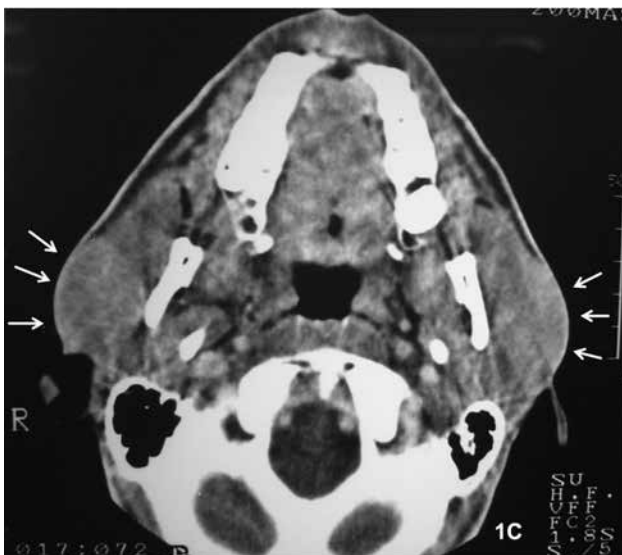


Figure 1C | Helical computed tomography of the soft tissues viewed with window scans clearly shows enlargement of the parotid glands (arrows). There is increased density in both glands, but no sign of intraglandular lesions.

In the literature, most of the cases of sialadenosis are related to chronic alcohol intake, although there have also been case reports related to anorexia nervosa and bulimia.^{2,6} Idiopathic sialadenosis is rarely seen or reported. According to our knowledge, there has been only one case of this condition published worldwide over the last 30 years.⁹

For this case, the question was raised whether an underlying squamous cell carcinoma on the esophageal tract, later diagnosed as an invasive tumor, could be considered the sole cause for triggering the salivary gland swelling.

This question is very speculative since the pathophysiology of sialadenosis is related to an autonomic neuropathy resulting in cytoplasmic swelling and enlargement of the salivary glands (mainly the parotids). On histopathological grounds, acinar cell hypertrophy with latter fatty infiltration is the prominent feature of the glandular parenchyma. Therefore, the role of a malignant disease in bringing about this whole process could be only acceptable if it was somehow affecting the autonomic nervous system. The malignancy observed in this case (squamous cell carcinoma on the esophageal tract) cannot be easily connected with the pathophysiology of sialadenosis. There is no report of salivary glands enlargement associated with head and neck malignancy as a distinct clinical feature so far. In addition, the usual history in relation to esophageal carcinoma is of a diagnosis in an advanced stage and poor prognosis due to the lack of symptoms, as was the case of the patient here reported.^{10,11} Dysphagia, weight loss, and blood loss are signs associated to esophageal carcinoma, and the patient showed dysphagia only eight months after his last consultation at our clinic.^{10,11}

On the other hand, one of the leading causes in sialadenosis is malnutrition, with bulimia and alcoholism being the most important leading factors in producing malnutrition.⁵

If one is to connect the malignancy seen in the patient as the trigger factor in the development of the glandular swellings, this would only be possible in association with some sort of lack of food absorption induced by the malignancy (given the location of the neoplasia, the esophageal tract), and consequently producing some degree of malnutrition.

CONCLUSIONS

The question raised in this report is so far merely speculative since there is no scientific evidence of association between sialadenosis and underlying malignant disease. The diagnosis that stands is of an idiopathic sialadenosis of parotid and submandibular glands.

REFERENCES

1. Pape SA, MacLeod RI, McLean NR, Soames JV. Sialadenosis of the salivary glands. *Br J Plastic Surg.* 1995 Sep;48(6):419-22.
2. Mandel L, Surattanont F. Bilateral parotid swelling: a review. *Oral Surg Oral Med Oral Pathol Oral Radiol Endod.* 2002 Mar;93(3):221-37. doi: <http://dx.doi.org/10.1067/moe.2002.121163>.
3. Coleman H, Altini M, Nayler S, Richards A. Sialadenosis: a presenting sign in bulimia. *Head Neck.* 1998 Dec;20(8):758-62. doi: 10.1002/(SICI)1097-0347(199812)20:8<758:AID-HED16>3.O.CO;2-N.
4. Mandel L, Patel S. Sialadenosis associated with diabetes mellitus: a case report. *J Oral Maxillofac Surg.* 2002 Jun;60(6):696-8. doi: <http://dx.doi.org/10.1053/joms.2002.33124>.
5. Scully C, Eveson J. Sialosis and necrotizing sialometaplasia in bulimia: a case report. *Int J Oral Maxillofac Surg.* 2004 Dec;33(8):808-10. doi: <http://dx.doi.org/10.1016/j.ijom.2004.02.002>.
6. Mandel L, Vakkas J, Saqi A. Alcoholic (beer) sialosis. *J Oral Maxillofac Surg.* 2005 Mar;63(3):402-5. doi: <http://dx.doi.org/10.1016/j.joms.2004.04.034>.
7. Amin MA, Bailey BM, Patel SR. Clinical and radiological evidence to support superficial parotidectomy as the treatment of choice for chronic parotid sialadenitis: a retrospective stu-

- Idiopathic sialadenosis involving parotid and submandibular glands: a case report

dy. *Br J Oral Maxillofac Surg.* 2001 Oct;39(5):348-52. doi: <http://dx.doi.org/10.1054/bjom.2001.0671>.

8. Ascoli V, Albedi FM, De Blasiis R, Nardi F. Sialadenosis of the parotid gland: report of four cases diagnosed by fine-needle aspiration cytology. *Diagn Cytopathol.* 1993 Mar;9(2):151-5. doi: 10.1002/dc.2840090208
9. Kim D, Uy C, Mandel L. Sialosis of unknown origin. *NY State Dent J.* 1998 Aug-Sep;64(7):38-40.
10. Pennathur A, Gibson MK, Jobe BA, Luketich JD. Oesophageal carcinoma. *Lancet.* 2013 Feb;381(9864):400-12. doi: 10.1016/S0140-6736(12)60643-6.
11. Rustgi AK, El-Serag HB. Esophageal carcinoma. *N Engl J Med.* 2014 Dec;371(26):2499-509. doi: 10.1056/NEJMra1314530.