

# Splenic congestion associated with acepromazine administration in dogs

## *Congestão esplênica associada à aplicação de acepromazina em cães*

Denise Cláudia TAVARES<sup>1</sup>; Fabiana Ferreira SOUZA<sup>2</sup>; Claudio Galvão OLIVAES<sup>3</sup>;  
Valeska RODRIGUES<sup>3</sup>; Thais Melo de Paula SEIXAS<sup>3</sup>;  
Ewaldo de MATTOS JUNIOR<sup>3</sup>; Gilson Hélio TONIOLLO<sup>1</sup>

<sup>1</sup> Universidade Estadual Paulista "Júlio de Mesquita Filho", Faculdade de Ciências Agrárias e Veterinárias, Departamento de Medicina Veterinária Preventiva e Reprodução, Jaboticabal – SP, Brazil

<sup>2</sup> Universidade Estadual Paulista "Júlio de Mesquita Filho", Faculdade de Medicina Veterinária e Zootecnia, Departamento de Reprodução Animal e Radiologia Veterinária, Botucatu – SP, Brazil

<sup>3</sup> Universidade de Franca, Franca – SP, Brazil

### Abstract

The effects splenic dilatation induced by acepromazine in a prospective, randomized study. Thirty-three adult mongrel dogs were divided into two groups designated as AG (acepromazine 0.05 mg/kg, i.v., n = 23) and CG (0.9% sodium chloride administered at a similar volume, n = 10). In both groups underwent sonographic examinations before (T0) and fifteen minutes (T15) after drug injection. The thickness spleen and splenic vein width were measured. Higher thickness was found in the AG group at T15 (2.47 cm) when compared to that at T0 (2.06 cm,  $p = 0.016$ ), while the T0 (2.33 cm) and T15 (2.39 cm) measures did not differ within the CG group. Moreover, the splenic vein width was higher ( $p = 0.013$ ) at T15 than at T0 in the AG group. Based on results of this study, we concluded that acepromazine, in doses of 0.05 mg/kg, promotes splenomegaly in dogs after fifteen minutes of the injection.

**Keywords:** *Canis lupus familiaris*. Phenothiazines. Splenomegaly.

### Resumo

Foram avaliados os efeitos de dilatação esplênica induzidos pela acepromazina em estudo do tipo prospectivo e randomizado. Trinta e três cães foram distribuídos em dois grupos designados como GA (acepromazina 0,05 mg/kg, i.v., n = 23) e GC (solução de cloreto de sódio 0,9% em volume semelhante ao GA, i.v., n = 10). Em ambos os grupos foi realizada ultrassonografia abdominal previamente à aplicação das substâncias (T0) e após 15 minutos (T15). A espessura do baço e a largura da veia esplênica foram mensuradas. Foi verificada maior espessura esplênica no GA no T15 (2,47 cm) quando comparado a T0 (2,06 cm,  $p = 0,016$ ), enquanto no GC não houve diferença significativa, sendo T0 (2,33 cm) e T15 (2,39 cm). Ainda, a largura da veia esplênica foi maior no T15 ( $p = 0,013$ ) comparado a T0 no GA. Baseado nos resultados encontrados, pode-se concluir que a acepromazina na dose de 0,05 mg/kg induz a esplenomegalia em cães após 15 minutos da aplicação.

**Palavras-chave:** *Canis lupus familiaris*. Fenotiazínicos. Esplenomegalia.

### Introduction

Laparoscopy is a minimally invasive technique that has been established in veterinary medicine due to its numerous advantages (MATYJASIK et al., 2011). One of the most common complications of this technique is spleen laceration, which usually occurs at the time of Veress needle insertion or trocar. In this situation, the laparoscopy is converted into a laparotomy, culminating with a splenectomy due to the hemorrhage caused by the puncture. Although the spleen is not necessary for survival, this lymphoid

organ has important immune functions, such as bacterial clearance of the bloodstream and antibody production (MARQUES et al., 2002). Moreover,

#### Correspondence to:

Fabiana Ferreira de Souza  
Universidade Estadual Paulista, Faculdade de Medicina Veterinária e Zootecnia  
Departamento de Reprodução Animal e Radiologia Veterinária  
Distrito de Rubião Junior, s/nº  
CEP 18618-970, Botucatu, SP, Brazil  
e-mail: fafesouza@fmvz.unesp.br

Received: 13/12/2013  
Approved: 17/11/2014

the spleen is responsible for filtrating large blood volumes; this process removes senescent and altered erythrocytes and corpuscular inclusion (MARQUES et al., 2002). Teixeira et al. (2008) reported that splenectomy results in a high rate of sepsis.

Placing the Veress needle with open techniques has been considered to reduce laparoscopy impact on the spleen (SCHIOCHET, 2006) but the use of drugs that cause splenomegaly results in a higher risk of spleen lacerations.

Splenomegaly is associated with many causes, including the administration of phenothiazine tranquilizers, which are extensively used in veterinary medicine (O'BRIEN; WALLER; OSGOOD, 2004). Among the phenothiazines, acepromazine is frequently used to tranquilize animals (LEMKE, 2007), it is relatively safe (HALL; CLARKE, 1987) and is low in cost. However, Paula et al. (2010) described an association between the acepromazine use in dogs and spleen lacerations during laparoscopy.

O'Brien, Waller and Osgood (2004) found a significant increase in the maximum and minimum diameters of the spleen after thiopental sodium and acepromazine administration, but no change was observed after infusion of propofol. Wilson, Evans e Carpenter (2004) analyzed the effects of anesthetic protocols involving acepromazine (0.044 mg/kg) and butorphanol (0.22 mg/kg) on splenic size and hematological profiles and found decreased hematocrit values.

Acepromazine is largely used in veterinary anesthesia, but in the literature have a few research about the effect of this drug on the spleen. The aim of this study was to investigate the effects of acepromazine (0.05 mg/kg) on splenomegaly as measured by ultrasound.

## Materials and Methods

### *Ethical aspects*

This study was approved by the Institution's Animal Experimentation Ethics Committee (protocol number 003/10).

### *Animals*

Thirty-three healthy, adult mongrel dogs weighing  $19.1 \pm 6.5$  kg were used. Before the study, the animals were submitted to clinical, hematological (complete blood count and polymerase chain reaction to *Ehrlichia* sp) and coproparasitologic. Animals that showed any abnormalities in the hematology or clinical examination were not included in the study.

### *Experimental design*

The dogs were divided into two groups designated as AG (n = 23) and CG (n = 10). The AG group received 0.05 mg/kg acepromazine; the CG group received saline solution (0.9% sodium chloride) in the same volume of AG. In both groups, the solutions were administered intravenously via the cephalic vein.

Spleen measurements were performed on both groups before administration (T0) and 15 minutes after administration (T15).

### *Sonographic evaluation*

The dogs were evaluated following a 12-hour food fast and 4-hour water fast. The dogs were maintained in the supine position with the spine aligned. The abdominal cavity was inspected using an 8-MHz sectorial transducer coupled to the ultrasound (Philips Envision HD, Andover, MA, USA). Evaluation included inspection of spleen echotexture and splenic dimensions (thickness and splenic vein width). The thickness (maximum) and splenic vein width were measured positioning the probe in a transverse plane to splenic major axis, on hilar region, using the caliper from machine. All measurements were done pre- and post-injection in both groups.

### *Statistical analysis*

The data are presented as means and their standard deviations. The statistical analysis was performed using the computer program SigmaPlot v.11. All data were submitted to a Shapiro-Wilk normality test. Comparisons between values from T0 and T15

in each group were made using Mann-Whitney rank sum test. The significance level was set at  $p \leq 0.05$ .

## Results

Ultrasound examination in both groups showed normal echotexture patterns for the species (Figure 1) at T0 and T15. The echogenicity of the spleen was higher than that of the renal cortex, and the hepatic parenchyma and splenic vein were easily visualized in the hilar region.

The spleen measure results are described in table 1. The AG group showed an increase in spleen thickness ( $p = 0.016$ ) and splenic vein width ( $p = 0.013$ ), but there were no differences in these measures between T0 and T15 in the CG group.

## Discussion

The initial fifteen minutes in the laparoscopic procedures it's complicated time, because in these moments occur most events, like compression of the diaphragm and important vessels (MATYJASIK et al., 2011), furthermore with the insert of trocar may cause injuries in organs and tissues.

Phenothiazines have been widely used for both sedation and premedication in several animal species (LEMKE, 2007). Studies suggest that these tranquilizers interfere with dopamine action in the brain (JONES, 1972).

The acepromazine dosage employed in the present study was recommended by Lemke (2007) for tranquilization in dogs. The data obtained in the

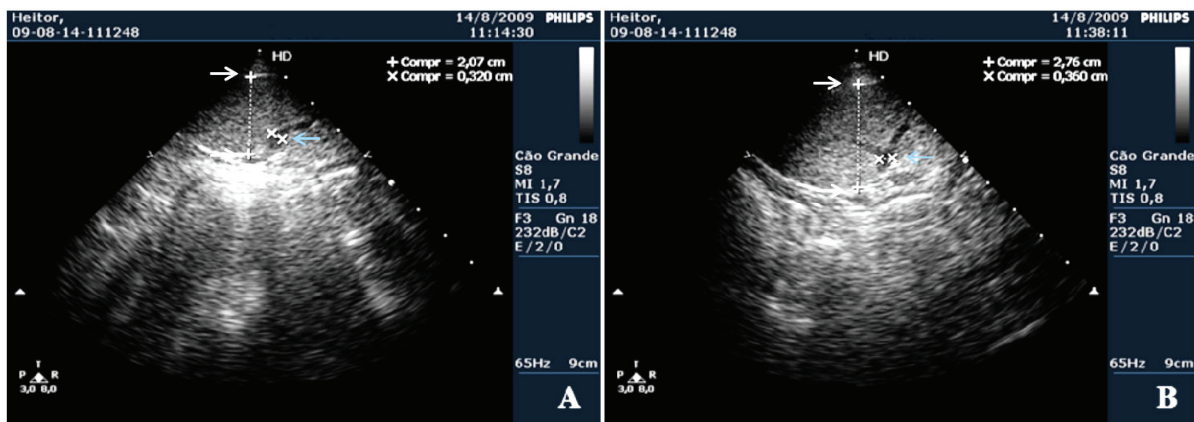


Figure 1 – Sonographic image of spleen from a dog (probe positioned in transverse plane to splenic major axis). Splenic thickness and splenic vein width pre- (A) and 15 min post- (B) acepromazine injection. White arrows indicating the line splenic thickness measurement and blue arrows indicating splenic vein width measurement

Source: personnel file

Table 1 – Mean  $\pm$  standard deviation of splenic measures in dogs treated with acepromazine group (AG) or control group (CG)

Measures	AG		CGa	
	T0	T15	T0	T15
Thickness (cm)	2.06 $\pm$ 0.28	2.47 $\pm$ 0.39*	2.33 $\pm$ 0.56	2.39 $\pm$ 0.71
Splenic vein width (cm)	0.33 $\pm$ 0.09	0.41 $\pm$ 0.14*	0.34 $\pm$ 0.08	0.37 $\pm$ 0.08

\* Significant difference ( $p < 0.05$ ) between T0 and T15 within the acepromazine-group (AG) or control group (CG)

study confirm those described by O'Brien, Waller and Osgood (2004), who described splenic dilation after acepromazine administration. Disagreeing with these authors, Baldo et al. (2012) found no difference in spleen volume by computed tomography after acepromazine use (0.03 mg/kg). These results may indicate that with lower dosages there is no effect on the spleen, but the increase may occur with a 0.044 mg/kg acepromazine dose (WILSON; EVANS; CARPENTER, 2004). The great number of innervated fibers controlled by the adrenergic system is one possible explanation for the increase in spleen size after acepromazine administration; this drug promotes adrenal suppression leading to relaxation of the splenic capsule and subsequent splenomegaly (LANG; EGLIN; HENRY, 1979).

The data collection times in this study were based on the time from insertion of the first trocar-cannula to establishment of pneumoperitoneum, which is considered the critical period for splenic injuries. Nevertheless, splenic sequestration promoted by acepromazine can last up to 24 hours (LANG; EGLIN; HENRY, 1979).

Wilson, Evans and Carpenter (2004) described reduced hematocrit values after acepromazine administration as a premedication in dogs and observed that this change was due to splenic red blood cell sequestration. Picioli et al. (2013) reported that administration of 0.1 mg/kg acepromazine by intramuscular injection induced a reduction in hematocrit and the total erythrocyte number for up to 8 hours after administration and hypothesized that this finding occurred due to splenic sequestration. This sequestration can be detrimental to some animals (WILSON; EVANS; CARPENTER, 2004), especially those that are hematological impaired prior to surgery. Mechanism of splenomegaly associated with the acepromazine administration is not known but may be related to the  $\alpha 1$ -adrenergic blockade leading to smooth muscle relaxation and vasodilatation with

consequent passive congestion; these changes allow stretching of the spleen capsule's smooth muscle fibers, with enlargement and the increased number of cells (LANG; EGLIN; HENRY, 1979; O'BRIEN; WALLER; OSGOOD, 2004; PARRY; ANDERSON, 1983; WILSON; EVANS; CARPENTER, 2004).

The increase in splenic vein thickness in dogs that received acepromazine may also be explained by the effects of acepromazine, which is known to promote vasodilatation and consequent hypotension (MEALEY; MATTHEWS, 1999).

Although splenomegaly was observed in a study using 0.044 mg/kg acepromazine, Wilson, Evans and Carpenter (2004) found lower spleen measure values when acepromazine was used with butorphanol, propofol and halothane. Thus, other drugs seem to influence acepromazine effect because the spleen measurements were higher when acepromazine was administered with butorphanol, thiopental and halothane. Nevertheless, splenomegaly occurred in all associations, with a 22% decrease in hematocrit, corroborating the results found in the present study.

Splenomegaly induced by acepromazine administration is a complication of invasive procedures in the abdominal cavity of dogs, especially those with hematological disorders prior to surgery. Considering this fact, other preanesthetic protocols can be indicated to avoid spleen trauma or injury that can compromise the indicated procedure, especially when the procedure involves laparoscopy.

## Conclusions

Based on the results of this research, it's possible to conclude that acepromazine in doses of 0.05 mg/kg promotes splenomegaly in dogs after fifteen minutes of the injection and should be avoided or used with caution as a premedication in dogs that are undergoing laparoscopy.

## References

- BALDO, C. F.; GARCIA-PEREIRA, F. L.; NELSON, N. C.; HAUPTMAN, J. G.; SHIH, A. C. Effects of anesthetic drugs on canine splenic volume determined via computed tomography. **American Journal of Veterinary Research**, v. 73, n. 11, p. 1715-1719, 2012.
- HALL, L. W.; CLARKE, K. W. Anestesia do cão. In: HALL, L. W.; CLARKE, K. W. **Anestesia veterinária**. 8. ed. São Paulo: Manole, 1987. p. 331-369.
- JONES, R. S. A. A review of tranquilization and sedation in large animals. **Veterinary Records**, v. 90, n. 22, p. 613-617, 1972.
- LANG, S. M.; EGLIN, R. M.; HENRY, A. C. Acetylpromazine administration: its effect on canine haematology. **Veterinary Records**, v. 17, n. 105, p. 397-398, 1979.
- LEMKE, K. A. Anticholinergics and sedatives. In: TRANQUILLI, W. J.; THURMON, J. C.; GRIMM, K. A. **Lumb & Jones' veterinary anesthesia and analgesia**. 4th ed. Oxford: Blackwell Publishing, 2007. p. 203-239.
- MARQUES, R. G.; PETROIANU, A.; OLIVEIRA, M. B. N.; BERNARDO FILHO, M. Importância da preservação de tecido esplênico para a fagocitose bacteriana. **Acta Cirurgica Brasileira**, v. 17, n. 6, p. 388-393, 2002.
- MATYJASIK, H.; ADAMIAK, Z.; PESTA, W.; ZHALNIAROVICH, Y. Laparoscopic procedures in dogs and cats. **Polish Journal of Veterinary Science**, v. 14, n. 2, p. 305-316, 2011.
- MEALEY, K. A.; MATTHEWS, N. S. Drug interactions during anesthesia: general principles. **Veterinary Clinics of North America: Small Animal Practice**, v. 29, n. 3, p. 629-643, 1999.
- O'BRIEN, R. T.; WALLER, K. R.; OSGOOD, T. L. Sonographic features of drug-induced splenic congestion. **Veterinary Radiology Ultrasound**, v. 45, n. 3, p. 225-227, 2004.
- PARRY, B. W.; ANDERSON, G. A. Influence of acepromazine maleate on the equine hematocrit. **Journal of Veterinary Pharmacology and Therapeutics**, v. 6, n. 2, p. 121-126, 1983.
- PAULA, T. M.; TONIOLLO, G. H.; HONSHO, D. K.; DUQUE, C. T. N.; VIEIRA, M. C. Esplenomegalia pelo uso de acepromazina em cães submetidos à biópsia prostática por videolaparoscopia. In: ENCONTRO DE PÓS-GRADUANDOS DA UNESP – FCAV, 6., 2010, Jaboticabal. **Anais...** Jaboticabal: Faculdade de Ciências e Veterinárias, 2010. p. 1.
- PICIOLI, A.; MARTINI, M. V.; MINERVINO, A. H. H.; DIAS, L. G. G. G.; MATTOS JUNIOR, E. O uso da acepromazina, dexmedetomidina e xilazina na sedação em cães: alterações hematológicas e bioquímicas. **Revista Brasileira Ciência Veterinária**, v. 20, n. 1, p. 13-19, 2013.
- SCHIOCHET, F. **Ovário-salpingo-histerectomia laparoscópica em felinos hípidos**. 2006. 91 f. Dissertação (Mestrado) – Programa de Pós-Graduação em Ciências Veterinárias, Universidade Federal do Rio Grande do Sul, Porto Alegre, 2006.
- TEIXEIRA, F. M.; FERNANDES, B. F.; REZENDE, A. B.; MACHADO, R. R.; ALVES, C. C.; PEROBELLI, S. M.; NUNES, S. I.; FARIAS, R. E.; RODRIGUES, M. F.; FERREIRA, A. P.; OLIVEIRA, S. C.; TEIXEIRA, H. C. *Staphylococcus aureus* infection after splenectomy and splenic autotransplantation in BALB/c mice. **Clinical Experimental Immunology**, v. 154, n. 2, p. 255-263, 2008.
- WILSON, D. V.; EVANS, A. T.; CARPENTER, R. E. The effect of four anesthetic protocols on splenic size in dogs. **Veterinary Anaesthesia Analgesia**, v. 31, n. 2, p. 102-108, 2004.