


Infectious diseases in aquarium ornamental pet fish: prevention and control measures*

Doenças infecciosas em peixes ornamentais de aquário: medidas de prevenção e controle

Pedro Henrique Magalhães Cardoso¹ ; Andrea Micke Moreno¹; Luisa Zanolli Moreno^{1,2}; Carolina Helena de Oliveira¹, Francisco de Assis Baroni³; Samara Rita de Lucca Maganha⁴; Ricardo Luiz Moro de Sousa⁴; Simone de Carvalho Balian¹

¹ Universidade de São Paulo, Faculdade de Medicina Veterinária e Zootecnia, Departamento de Medicina Veterinária Preventiva e Saúde Animal, São Paulo – SP, Brazil

² Centro Universitário Max Planck, Indaiatuba – SP, Brazil

³ Universidade Federal Rural do Rio de Janeiro, Departamento de Microbiologia, Seropédica – RJ, Brazil

⁴ Universidade de São Paulo, Faculdade de Zootecnia e Engenharia de Alimentos, Departamento de Medicina Veterinária, Pirassununga – SP, Brazil

*Scientific revision article originating from the doctoral thesis of the student Pedro Henrique Magalhães Cardoso.

ABSTRACT

Aquarium ornamental pet fish constitute a major segment in the pet industry, with the United States, Europe, and Japan dominating the market. There are approximately 1,500 marine fish species and over 4,500 freshwater fish species commercialized as aquarium ornamental pet fish. Fish are the fourth most common pet present in Brazilian homes. In Brazil, aquarium ornamental pet fish can be marketed and distributed from different parts of the Brazilian territory and the world. Commercialization and circulation of living animals without the use of adequate prophylactic management procedures enables dissemination of a number of agents responsible for infectious diseases. Aquarium pet fish can also carry pathogenic agents, of bacterial, viral, fungal, or parasitic etiology, that may have a zoonotic feature endangering the persons handling the animals. This review presents the main pathogenic infectious agents of bacterial, viral, and fungal etiology that affect aquarium pet fish, as well as the prevention and control measures to ensure sanitary excellence in this segment.

Keywords: Ornamental fish disease. Bacteria. Virus. Fungi. Animal health.

RESUMO

Peixes ornamentais de aquário representam um grande segmento no mercado de animais de estimação, no qual Estados Unidos, Europa e Japão dominam. São aproximadamente 1.500 espécies de peixes marinhos e em torno de 4.500 de espécies de água doce comercializados com fins ornamentais. O peixe é a quarta espécie mais comum nos domicílios brasileiros. Peixes ornamentais de aquário são comercializados e distribuídos em diferentes partes do território nacional e do mundo. O comércio e circulação de animais vivos sem o uso de procedimentos de manejo profilático adequados possibilita a disseminação de inúmeros agentes patogênicos. Peixes ornamentais de aquário carregam consigo agentes patogênicos de etiologia bacteriana, viral, fúngica e parasitária, sendo alguns de caráter zoonótico colocando em risco pessoas que os manipulam. O objetivo desta revisão é apresentar os principais agentes infecciosos patogênicos - de natureza bacteriana, viral e fúngica - que acometem peixes ornamentais de aquário, bem como os métodos de prevenção e controle que permitam excelência no segmento.

Palavras-chave: Peixes ornamentais de aquários. Bactérias. Vírus. Fungos. Saúde animal.

Correspondence to:

Pedro Henrique Magalhães Cardoso
 Universidade de São Paulo, Faculdade de Medicina Veterinária
 e Zootecnia, Departamento de Medicina Veterinária
 Preventiva e Saúde Animal
 Av. Prof. Dr. Orlando Marques de Paiva, 87
 CEP: 05508-270, São Paulo – SP, Brazil
 e-mail: pedrohenriquemedvet@usp.br

Received: November 10, 2018

Approved: May 07, 2019

How to cite: Cardoso PHM, Moreno AM, Moreno LZ, Oliveira CH, Baroni FA, Maganha SRL, Sousa RLM, Balian SC. Infectious diseases in aquarium ornamental pet fish: prevention and control measures. *Braz J Vet Res Anim Sci.* 2019;56(2): e151697. <https://doi.org/10.11606/issn.1678-4456.bjvras.2019.151697>.

Introduction

Aquarium ornamental pet fish constitute a major segment in the pet industry, with the United States, Europe, and Japan dominating the market (Noga, 2010). In 2016 in Brazil, which holds second place in the world's pet market, was responsible for moving more than R\$18.9 million in Brazilian economy. According to the Brazilian Institute of Geography and Statistics (IBGE), fish are the fourth most common pet present in Brazilian homes, with approximately 18 million animals, ranking only behind dogs, cats, and birds (Associação Brasileira da Indústria de Produtos para Animais de Estimação, 2017). Though the ornamental fish market's contribution to world trade in terms of value is small overall, the sector plays a relevant role in terms of poverty alleviation in developing countries and marine preservation. Coastal and riverine communities are able to utilize ornamental fish, which can be a sustainable and renewable resource, as a source of income. The value of ornamental fish trade has grown significantly over the past decades. Between 2000 and 2011, global exports of ornamental fish increased from US\$181 million to US\$372 million (Food and Agriculture Organization of the United Nations, Analysis and Information on World Fish Trade, 2017).

In Brazil, aquarium ornamental pet fish can be marketed and distributed from different parts of the Brazilian territory and the world, as long as it follows IBAMA and MAPA's requirements (Brasil, 2008a, 2008b, 2011, 2012). There are approximately 1,500 marine fish species (most obtained with extractive fishing) and over 4,500 freshwater fish species (almost all bred in captivity) (Whittington & Chong, 2007).

Translocation of aquatic animals has allowed ornamental aquarium pet fish from different places around the world to be released in Brazil, and some of them even have higher reproductive rates because of the propitious climate (Alves et al., 2007; Lincoln et al., 2013).

Trade and circulation of living animals without fulfilling technical standardized and safety procedures enable dissemination of a number of agents responsible for infectious diseases and stressful situations, which causes high mortality rates (Figure 1). The emergence of diseases in consequence of the absence of biosecurity also restricts the improvement of aquaculture sectors because of productivity losses and trade restrictions (Cardoso & Balian, 2016; Cardoso et al., 2017c, 2017b).

Ornamental aquarium pet fish can also carry pathogenic agents of bacterial, viral, fungal, or parasitic etiology that may have zoonotic features, endangering the individuals who handle the animals (Beran et al., 2006; Lowry & Smith, 2007; Weir et al., 2012; Fulde & Valentin-Weigand, 2013; Gauthier, 2015).

Considering the consolidation of this market worldwide, its clear improvement, the advance of technology in productive systems, and the available biosecurity, the aim of this review was to present the main pathogenic infectious agents of bacterial, viral, and fungi etiology that afflict ornamental aquarium fish, as well as to discuss the prevention and control measures to ensure sanitary excellence in this segment.

Bacterial Diseases

Bacterial diseases are common in ornamental fish and are more frequently associated with ubiquitous bacteria from the aquatic environment. Overall, the clinical signs include ulcerative and hemorrhagic lesions in the skin (Figure 2a), corneal opacity (Figure 2 b-c), systemic infections, and septicemia (Figure 2d) (Roberts et al., 2009).

In fish, this type of infection involves a combined action of diverse aspects, including the environment, the host (immunological function, host susceptibility, etc.), and specific factors for each pathogen, such as its virulence (Roberts et al., 2009). Most bacteria are part of the intestinal microbiota of the fish or of the water, and remains in balance with other aquatic organisms in the ecosystem. However, when there is an increase in organic or inorganic matter concentration, it allows bacteria to reproduce easily and reach opportunistic conditions, becoming pathogenic to the susceptible fish. To reduce this event, preventive measures are required to control these pathogens.

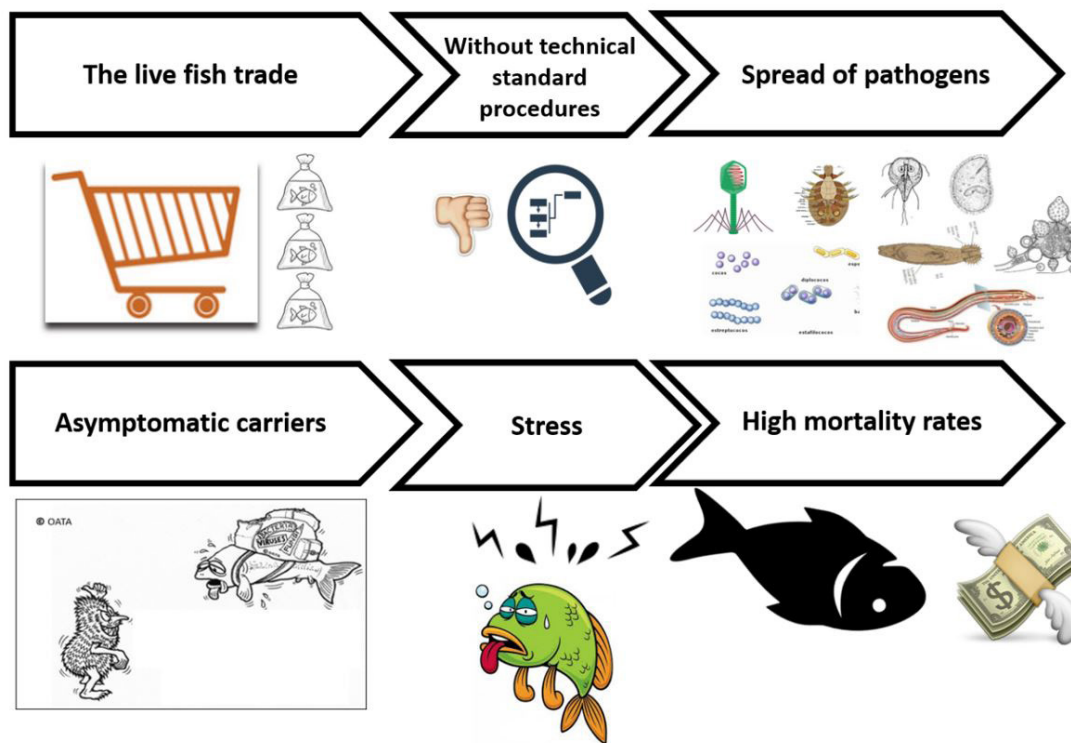


Figure 1 –Disease transmission chain in ornamental fish trade.

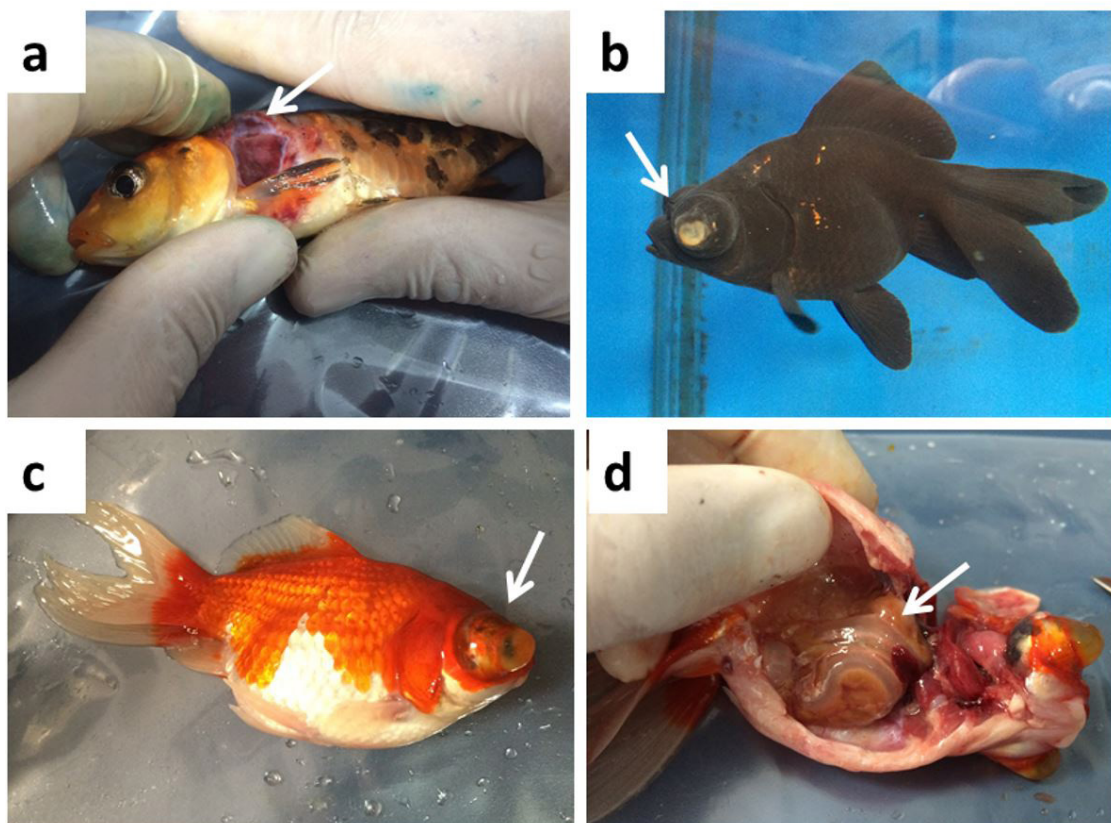


Figure 2 –(a) Hemorrhagic lesions in skin in *Cyprinus carpio*; (b), (c) corneal opacity in *Carassius auratus*; (d) septicemia in *Carassius auratus*.

Gram-negative bacteria

Most of the bacteria that affect ornamental fish are classified as gram-negative. Species of genus *Aeromonas*, *Citrobacter* (Roberts et al., 2009), *Edwardsiella* (Lowry &

Smith, 2007; Hawke et al., 2013; Humphrey et al., 1986), *Francisella* (Camus et al., 2013; Colquhoun & Duodu, 2011; Lewisch et al., 2014), *Flavobacterium* (Declercq et al., 2013, 2015; Guz et al., 2014; Verma et al., 2015), *Plesiomonas* (Nisha

et al., 2014), *Shewanella* (Peçala et al., 2015), and *Vibrio* are the most common genera (Abd El-Galil & Mohamed, 2012; Hashem & El-Barbary, 2013; Martins et al., 2010; Tendencia, 2004).

The gram-negative species that are most commonly reported in ornamental aquarium fish are *Aeromonas hydrophilla*, *Aeromonas veroni*, *Aeromonas caviae* (Citarasu et al., 2011; Grim et al., 2013; Yucel et al., 2005), *Citrobacter freundii* (Gallani et al., 2016), *Shewanella putrefaciens* (Altun et al., 2014; Beaz-Hidalgo et al., 2015; Chen et al., 1997), and *Flavobacterium columnare* (Declercq et al., 2013).

Pathology

Clinical signs of motile aeromonad infection range from superficial to deep skin lesions, to a typical Gram-negative bacterial septicemia, with or without skin lesions. Skin lesions include variously sized areas of hemorrhage and necrosis on the skin and base of the fins. These may progress to reddish or gray ulcers with necrosis extending to the muscle. Ulcers may progress to hemorrhagic septicemia, with exophthalmos, a distended abdomen that has serosanguinous fluid, visceral petechiation, and a hemorrhagic and swollen lower intestine and vent. Peracute infections are not associated with skin lesions. Anorexia and dark color are most common with systemic disease (Roberts et al., 2009).

Flavobacterium columnare, responsible for “columnaris infection” is relatively common in ornamental aquarium fish and easily recognized by the distinguishing clinical signs, beginning with pale discolored areas on the skin, usually surrounded by reddish zones (Figure 3a). Rods are easily observed (Figure 3b) upon examining smears of the wet mounts of the lesions by Gram staining technique. It is

an agent that does not grow well *in vitro* in usual bacterial culture media (Declercq et al., 2013).

The species of fish most reported by the previous authors are *Carassius auratus*, *Cyprinus carpio*, *Danio rerio*, *Xiphophorus maculatus*, *X. helleri*, *Poecilia latipinna*, *P. reticulata* and *P. sphenops*, but any kind of fish can be infected.

Gram positive bacteria

Although it is less common, Gram-positive bacteria can also cause infections in ornamental fish. The most common genus is *Streptococcus* (Russo et al., 2006; Tukmechi et al., 2009).

Mycobacteriosis

Fish mycobacteriosis is a granulomatous disease occurring in aquarium and cultured food fish. The most important species causing mycobacteriosis in fish are non-tuberculous mycobacteria, that include *Mycobacterium chelonae*, *M. fortuitum*, and *M. marinum*. Other species known to cause mycobacterial infections in fish include *M. abscessus*, *M. chesapeaki*, *M. flavescens*, *M. gordonae*, *M. haemophilum*, *M. kansasii*, *M. monteforense*, *M. neoaurum*, *M. peregrinum*, *M. salmoniphilum*, *M. scrofulaceum*, *M. simiae*, *M. shottsii*, and *M. terrae* (Pate et al., 2005; Puk et al., 2017; Sirimalaisuwan et al., 2016; Wu et al., 2012).

The zoonotic nature of mycobacteriosis and massive economic losses in the aquaculture industry highlight the need for rapid identification and treatment of mycobacterial infections (Puk et al., 2017).

Pathology

Emaciation, poor growth, retarded sexual maturation, or decreased reproductive performance may be the only clinical signs of mycobacteriosis. Other lesions include

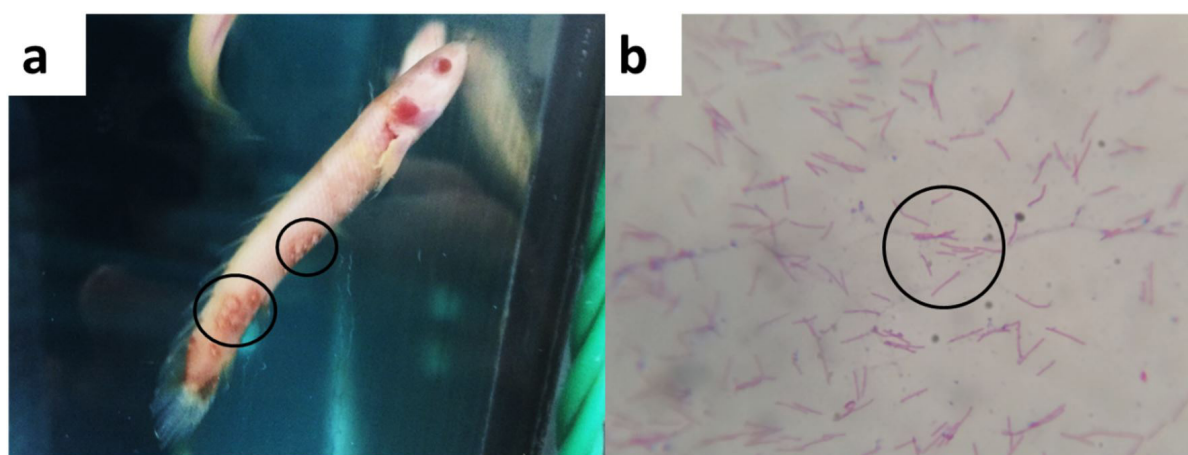


Figure 3 – (a) Pale discolored areas in skin, usually surrounded by reddish zones in *Polypterus senegalus*; (b) gram-negative rod smears from injured areas (magnification 100X).

skeletal deformities, chronic, nonhealing, shallow to deep ulcers or fin erosion. Internally, 1 – 4 mm white nodules may be present on the viscera, especially hypertrophic kidney or spleen. A more acute form of the disease, associated with abdominal distention and dermal edema, is less common (Pate et al., 2005; Puk et al., 2017; Whipps et al., 2012).

Based on the previous papers, perhaps the most studied fish is *Danio rerio*, but several other species used as aquarium ornamental pet fish are infected by this class of bacteria, like *Acipenser ruthenus*, *Betta splendens*, *Carassius auratus*, *Corydora spp.*, *Colisa lalia*, *Cyprinus carpio*, *Gambusia gaigei*, *Xiphophorus helleri*, *Trichogaster lalius*, *Trichogaster trichopterus*, *Labidochromis caeruleus*, *Mikrogeophagus ramirezi*, *Microgeophagus altispinosus*, *Paracheirodon innesi*, *Poecilia latipinna*, *Pseudotropheus lombardoi*, *Pterophyllum scalare*, although any kind of fin fish can be infected.

Potentially zoonotic bacteria

Apart from causing diseases in fish, some gram-negative bacteria, such as *Aeromonas hydrophilla*, *A. caviae*, *A. veroni*, *Shewanella putrefaciens*, *Edwardsiella tarda*, *Pseudomonas alcaligenes*, among others, may also have a zoonotic feature (Humphrey et al., 1986; Lehane & Rawlin, 2000; Sreedharan et al., 2011; Suzuki et al., 2013; Yucel et al., 2005) and are common in aquatic environments.

The genus *Aeromonas* can affect several structures and organic systems, causing gastroenteritis, infections in superficial wounds, respiratory and urinary infections, septicemia, meningitis, and endocarditis (Bizani & Brandelli, 2001; Guerra et al., 2007; Parker & Shaw, 2011). Gastroenteritis is the most frequent condition, and in more severe situations, peritonitis, colitis, and cholangitis may occur. The species frequently identified are *A. hydrophila*, *A. caviae*, and *A. veronii* biovar *sobria*, which represent 85% of the human infectious gastroenteritis cases. The species *A. caviae* and *A. veronii* biovar *sobria* are generally associated with the “traveler’s diarrhea” (Guerra et al., 2007).

Shewanella putrefaciens can cause a wide range of clinical signs when it infects humans, including septicemia, skin and soft tissue infections, biliary tract infection, peritonitis, and emphysema (Chen et al., 1997; Holt et al., 2005; Janda, 2014). The most common mechanism of infection is traumatic events that enable the inoculation of the agent from abrasive surfaces (Beaz-Hidalgo et al., 2015; Janda, 2014). These are infectious processes that represent extreme risk for professionals who work with fish.

In Japan and China, mycobacteriosis is known as an important occupational disease for those who work with aquariums, and it causes chronic granulomatous lesions

that are difficult to treat. In some cases, surgical removal is required because of the inefficiency of antibiotic treatments. In infrequent events, it becomes necessary to amputate the injured limbs. *Mycobacterium marinum*, *M. fortuitum*, and *M. chelonae* are the most common species that afflict humans (Essa et al., 2009; Cheung et al., 2012; Pate et al., 2005; Whipps et al., 2012), and are frequently associated with the absence of good practice in animal management (Yanong & Pouder, 2010).

Mycobacteria are highly relevant for ornamental fish professionals because of the risk of occurrence once the disease has an occupational characteristic. It is fundamental to prevent this type of infection with the rigorous adoption of good handling practices and good management in all parts of the business of maintenance and commercialization of aquatic organisms.

Viral Diseases

Viral diseases are considered the cause for the major economic losses in worldwide aquaculture. Furthermore, they predispose the emergence of other secondary diseases. The losses appear to be caused by obstacles in the prevention and control measures associated with the absence of effective treatments against viral infections (Dopazo & Bandín, 2009; Nakajima et al., 1998). Depending on the etiological agent involved, the mortality rate can reach 100%.

More than 125 viruses have been identified in fish, and with the identification through molecular techniques, new findings are being made every day (Essbauer & Ahne, 2001). The families Alloherpesviridae (DNA), Iridoviridae (DNA), Poxviridae (DNA), Nodaviridae, and Rhabdoviridae (RNA) host several species that cause fish diseases with high rates of morbidity and mortality (Ahne et al., 2002; Gotesman et al., 2013; Hegde et al., 2003; Whittington et al., 2010; Yong et al., 2017).

Alloherpesviridae family

The family Alloherpesviridae (DNA virus) has four genera: *Cyprinivirus*, *Batrachovirus*, *Salmonivirus* and *Ictalurivirus*. *Cyprinivirus* is the genus most frequently associated with ornamental fish diseases. It has been characterized for high specificity, and it promotes persistent infections with rare or even no clinical signs in adult animals (Hanson et al., 2011). *Cyprinid herpesvirus 1*, *Cyprinid herpesvirus 2*, and *Cyprinid herpesvirus 3* species belong to the genus *Cyprinivirus* and are associated with mass infections and high rates of mortality in carp (*Cyprinus carpio*) and goldfish (*Carassius auratus*) (Davison et al., 2013). Other fish species of the Cyprinidae family are susceptible as well.

Pathology

The disease caused by *Cyprinid herpesvirus 1* (*CyHV-1*) presents a worldwide distribution. It is characterized by proliferative skin lesions, and is usually associated with decreases in water temperature (Davison et al., 2013). It usually presents two phases: acute and recurrent. Acute phase afflicts juvenile fish causing high mortality rates. In the recurrent phase, the surviving adult shows proliferative lesions within the body (Davison et al., 2013; Sano et al., 1985; Sano et al., 1990, 1993). Fish that survive the acute phase become carriers and may spread the virus by vertical or horizontal transmission (Davison et al., 2013).

Disease by *Cyprinid herpesvirus 2* (*CyHV-2*) was primarily identified in Japan in 1992, and it caused events of mass mortality in goldfish piscicultures in Taiwan (Chang et al., 1999), the United States (Goodwin et al., 2006), United Kingdom (Jeffery et al., 2007), and Australia (Stephens et al., 2004). The outbreaks involved fish of all ages and occurred especially in spring and fall, or after intense handling of the fish, or severe decreases in water temperature in wholesaler markets (Becker et al., 2014).

Cyprinid herpesvirus 2 (*CyHV-2*) was also identified, in 2003, in piscicultures of Western Australia (Stephens et al., 2004). Becker et al. (2014) suggested that goldfish with subclinical infections passed through the quarantine period and contacted domestic stocks in the live animal market. A survey made with sick and moribund fish collected in retail stores in Sidney revealed that 17% of the animals were carriers of the virus (Becker et al., 2014).

Cyprinid herpesvirus-3 (*CyHV-3*), also known as Koi Herpesvirus (KHV), is one of the most important pathogens that afflict common carps (*Cyprinus carpio*) and the ornamental variety koi. The virus *CyHV-3* induces a severe disease known as koi herpesvirus disease (KHVD), and it is associated with mass morbidity and mortality, reaching populations in cultivation and in the wild. It represents an important threat for carp (Bretzinger et al., 1999; Garver et al., 2010; Hedrick et al., 2000). Fish that recover from KHVD have DNA of the *CyHV-3* virus in their liver, heart, gills, and eyes, and it may also be present in epithelial cells in the gastrointestinal tract or in leukocytes. Surviving carp are carriers of *CyHV-3* and can excrete the virus, especially after stressful conditions. Goldfish (*Carassius auratus*) have already been reported as asymptomatic carriers of the virus, which is an important pathogen of global interest due to the losses in commercial breeding systems (Gotesman et al., 2013). The KHVD is listed as a notifiable disease by the World Organization for Animal Health (OIE).

Iridoviridae family

Viruses from three genera of the Iridoviridae family (iridoviruses) affect finfish. Ranaviruses and megalocytiviruses have emerged recently as important pathogens for cultured and wild finfish, known for the severity of the systemic diseases they cause, their global occurrence and the diversity of hosts affected in both marine and freshwater environments. Ranaviruses are also significant pathogens of amphibians. In contrast, lymphocystiviruses, although widespread in freshwater and marine finfish hosts, rarely cause economic losses (Whittington et al., 2010). Among the three, *Megalocytivirus* and *Lymphocystivirus* are the two most frequently reported in ornamental fish (Yanong & Waltzek, 2011; Yanong, 2013).

Pathology

Infections by *Megalocytivirus* have been reported in several species of ornamental fish and can cause significant economic losses worldwide (Nolan et al., 2015; Maganha, 2016). Clinical signs are nonspecific and resemble those seen in many other fish diseases. The most common clinical signs are darkened skin, irregular swimming (including rotating movements), or positioning on the surface of the water, increased respiratory movements, distention of the abdominal cavity, ulceration, hemorrhages (including punctate hemorrhages in the skin and gills), pallor of the gills, anemia, erosion of the fins, whitish stools, and high mortality rates. Necropsy shows necrosis in many internal organs, such as the spleen, kidneys, and liver. Other organs and tissues, including muscles, gonads, heart, gills, and gastrointestinal tract may also be affected. Some fish may have visible hemorrhagic fluid in the body cavity (Cardoso et al., 2017a).

Lymphocystis disease has been reported in over 125 different marine and freshwater fish species from 34 different families. The lymphocystiviruses are considered much less pathogenic (disease-causing) than their iridoviral relatives, the ranaviruses and megalocytiviruses, which can cause severe, systemic disease with higher mortalities. The most obvious sign is the appearance of small to moderate-sized, irregular, nodular, wart-like growths on the fins, skin, or gills (Cardoso & Balian, 2016; Yanong, 2013).

Fish with *Lymphocystis* normally do not behave differently from uninfected fish in the same group. However, if there are large numbers of nodules on the body or fins (Figure 4a), or if they cover a large portion of the gills, they may alter swimming or cause breathing patterns. The nodules represent groups of enlarged infected cells known as fibroblasts (Figure 4b), which are part of the connective tissues in the fish. These infected cells are 50,000–100,000x larger




Figure 4 – (a) Nodules on fins of *Chaetodon auriga*; (b) wet mount of fin, fibroblast nodules in infected cells of the fin (10x magnification) in *Chaetodon auriga*.

in volume than normal because they have become “virus factories,” using the infected cell’s machinery to produce more viruses; thus, they are filled with virus particles. After these “virus factory cells” have completed virus particle production, they burst and shed virus into the environment (Hossain et al., 2008; Rahmati-Holasoo et al., 2010; Yanong, 2013; Xu et al., 2014).

Fortunately, most cases of lymphocytes in hot water fish resolve after a few weeks, while maintaining good water quality / chemistry, good nutrition, correct population densities, and compatible batches, and eliminating other stressors. Culling (removing) infected fish from a population may help reduce overall loads of virus in the system as well as infection rate, but it is difficult to cull all affected fish because some infections may not be visible to the naked eye (Yanong, 2013). The disease caused by *Ranavirus* and some *Megalocytivirus* are listed as notifiable disease by the OIE.

Among the species of aquarium ornamental fish identified in Iridoviridae family by the previous authors are *Astronotus ocellatus*, *Carassius auratus*, *Cyprinus carpio*, *P. reticulata*, *Pygocentrus nattereri*, *Xiphophorus maculatus*, *Trichogaster trichopterus*, *Trichogaster lalius*, *Trichogaster labiosa*, *Trichogaster microlepis*, *Trichopodus trichopterus*, *Trichopodus leerii*, *Macropodus opercularis*, *Serrasalmus gibbus*, *Pangasius hypophthalmus*, *Pterophyllum scalare*, *Moenkhausia coastae*, *Branchio albolineatus*, *Misgurnos anguilicaudatus*, *Hypostomus Plecostomus*, *Arapaima gibas*, *Hemiodopsis gracilis*, and *Pomacanthus narevachus*, among several others.

Poxviridae family

The family Poxviridae (DNA virus) has the *Poxvirus* genus that causes carp edema virus (CEV), which is responsible for high mortality among juvenile koi, *Cyprinus carpio*. Characteristic signs in infected fish are swelling due to edema of the body and swimming at the surface of the pond. Based on clinical signs, the disease was named viral edema of carp (VEC). As the name ‘koi sleepy disease’ suggests, the most consistent behavioral sign are pronounced lethargy and unresponsiveness. The affected fish will often lie motionless, sometimes on their side, on the bottom of the pond or tank for long periods, as if sleeping. When disturbed by physical stimulation, the fish will swim for a short time and then resume their inactive state on the bottom of the pond (Way et al., 2017).

Carp edema virus disease/koi sleepy disease was first characterized from Japanese koi in 1974, and since then has been shown to be widespread across Japan where koi are cultured. The international trade in koi has likely led to the global spread of CEV with outbreaks documented in imported koi in North America and Europe (Hesami et al., 2015). In the United States, CEV has been associated with outbreaks in imported and domestic koi. The virus has recently been detected for the first time in the Southern hemisphere, on koi farms in Brazil (Viadanna et al., 2015).

Pathology

The affected fish will often lie motionless, sometimes on their side, on the bottom of the pond or tank for long periods, as if sleeping. When disturbed by physical stimulation, the fish will swim for a short time and then resume their inactive state on the bottom of the pond (Way et al., 2017). Until now, the main species of ornamental aquarium fish susceptible is *Cyprinus carpio*.

Nodaviridae family

Family Nodaviridae (RNA virus) includes the genus *Betanodavirus*, known since the 1980s, and is responsible for high rates of mortality, particularly in larval and juvenile stages of fishes. The virus has been reported worldwide, except for South America, especially in places where there are marine fish cultures. The disease has received several designations, such as viral nerve necrosis (VNN), fish encephalitis virus, viral encephalopathy, and retinopathy. In spite of being a virus that afflicts both freshwater and marine fish, it has already been reported in more than 40 species of fish hosts (22 families and 8 orders) (Shetty et al., 2012).

Several experimental infection studies have demonstrated that both marine and freshwater finfish are susceptible to betanodavirus infection. Diagnostic techniques are important to identify outbreaks of infection and track back the broodstock that may be acting as carriers. To date, PCR is the main diagnostic test that is being used by most laboratories (Keawcharoen et al., 2015; Volpe et al., 2017).

Pathology

Diseased fish show various clinical symptoms, which include reduced appetite, emaciation, color change (darkening), abnormal (whirling) swimming pattern, neurological dysfunction, exophthalmia, swim bladder hyperinflation, floating belly up with inflation of swim bladder, anorexia, gas accumulation, and extensive mortality. Diagnostic techniques are important to identify outbreaks of infection and track back the broodstock that may be acting as carriers. To date, PCR is the main diagnostic test that is being used by most laboratories (Keawcharoen et al., 2015; Volpe et al., 2017).

Rhabdoviridae family

The *Rhabdovirus carpio* virus, belonging to the family Rhabdoviridae (RNA virus), has a characteristic bullet shape, and causes the spring viremia of carp (SVC). It is responsible for mass mortality in various species of carp, including common carp (*Cyprinus carpio*). These species

are raised as a food fish in many countries and koi carp has been selectively bred for the ornamental fish industry. Thought to be present in Europe for decades, SVC virus was initially diagnosed in Yugoslavia. Since then, it has been identified in other European countries, Russia, Brazil, the Middle East, China, and North America (Alexandrino et al., 1998; Petty et al., 2012).

Pathology

In carp, the most common external signs of SVC are hemorrhages of the skin, exophthalmia, abdominal distension, and an inflamed or edematous venter. Internal signs are peritonitis, ascites, catarrhal and hemorrhagic enteritis, edematous viscera, and petechial hemorrhages of the internal wall of the swim bladder and skeletal muscle (Ahne et al., 2002). This is also an OIE notifiable illness.

The virus infected several ornamental cyprinids species like *Danio rerio* and *Carassius auratus*, among others. It can also affect some ictalurid fish.

Fungal Diseases

Oomycetes of the *Saprolegnia* order, such as *Aphanomyces*, *Saprolegnia* and *Aclhya*, are ubiquitous in the aquatic environment. Currently they are considering “pseudofungus”, because they belong in the Stramenopila Kingdom, but still are designated as aquatic fungus. They are usually secondary invaders of epithelial surfaces in amphibians, crustaceans and fish, and are associated with low-quality water and responsible for causing devastating infections in affected animals (Osman et al., 2010; Jiang et al., 2013).

Saprolegnia causes saprolegniosis, the most common “fungal disease” in ornamental aquarium fish. It is characterized by white or greyish cotton-like lesions within the body or flippers (Figure 5a) in freshwater fish, similar to cotton tufts, formed by the filamentous mycelium. Zoosporangias are formed in the hyphae extremity, normally are elongated and possesses zoospores (Figure 5b). The genus, which is a saprophyte and grows in organic matter, has an opportunistic feature, which means that the emergence of the “fungal” infection in fish is indicative of an imbalance in the aquatic system and low-levels of water quality (Van West, 2006).

Infection with *Aphanomyces invadans*, also known as epizootic ulcerative syndrome (EUS), is an OIE-listed disease. It has historically caused mass mortality in cultured and wild fish in Asia and Oceania and recently in North America and Africa (Afzali et al., 2015; Majeed et al., 2017; Iberahim et al., 2018; The World Organisation for Animal Health, 2017).




Figure 5 – (a) White cottony lesions on the body of *Baryancistrus* sp.; (b) slide stained with cotton blue, zoosporangias formed in hyphae extremity (10x magnification).

Pathology

The occurrence of skin lesions varies depending on the fish species as well as manifestation and ranges from crucial areas of intense inflammation and hyperaemia of the skin to deep ulcerations with uncovering of the lower muscle tissue. Early lesions are characterized by hemorrhagic bullae with small foci of ulceration and are often observed on the lateral surface (Iberahim et al., 2018).

Among the ornamental aquarium fish with fungal infection, the most cited by previous authors are *Carassius auratus*, *Cyprinus carpio*, *Poecilia reticulata*, *Poecilia sphenops*, *Xiphophorus maculatus*, *Xiphophorus helleri*.

Prevention and Control of Diseases in Ornamental Fish

Prevention and control for bacterial diseases

Good practices in management and prophylaxis are the keys to preventing bacterial diseases in fish. It is fundamental to acquire animals from places with effective sanitary control (capable of assuring the absence of certain agents and pathogens), to only accept animals without clinical signs, and that are kept in environments with excellent water quality and low levels of organic matter to decrease stress in fish (Crosby et al., 2014).

Aquariums that use a recirculation water system must, mandatorily, treat the recirculated water with proven efficient methods, such as filters with ultraviolet radiation and ozonation, to inactivate the bacteria present in the water (Sharrer & Summerfelt, 2007).

Ultraviolet radiation is absorbed by proteins and nucleic acids, promoting chromosome breakage, gene

mutation, and enzymatic inactivation, leading to death (Alexandre et al., 2008) of several fish pathogens, such as bacteria, viruses, fungi and parasites.

Ozone is a powerful oxidant agent widely used in aquaculture, both for disinfection (because it oxidizes fish pathogens) and as an improver of water quality (because it oxidizes organic matter, including coloration, odor, and nitrites) (Summerfelt, 2002).

Each of the methods for treating water, ultraviolet radiation or ozonation, can be used separately in recirculation systems, but when combined, have a potential effect in the control of fish pathogens (Park et al., 2013; Roberts et al., 2009; Sharrer & Summerfelt, 2007).

The application of these mechanisms represents an important preventive measure capable of reducing bacterial water load, and then to reduce occurrence of bacterial diseases (Park et al., 2013; Roberts et al., 2009; Sharrer & Summerfelt, 2007).

Reduction in dissemination of bacterial biological hazards in commercial fish establishments can also be minimized after adopting good practices in aquarium management, preventing the occurrence of cross contamination. It is essential to adopt exclusive and individual utensils and equipment for each system, avoiding cross contamination between aquatic systems (Kent et al., 2009). Associated with this practice, every utensil and piece of equipment must be sanitized with specific products used in aquaculture. A disinfectant widely used in worldwide aquaculture and regulated to sell in Brazil is Chloramine-T (Gaikowski et al., 2004).

It is impossible to maintain fish in sterile water, once commensal bacteria of skin and intestinal microbiota are constantly eliminated in the water. However, the practices

mentioned above can reduce, prevent, and control the occurrence of pathogenic agents in water as well as stressful situations for fish, resulting in a better life quality for the animals, minimization of diseases occurrence and controllable trade losses.

Prevention and control for viral diseases

The main preventive measure for viral diseases is the acquisition of animals from farms that prove conditions free of diseases of concern for the section (Becker et al., 2014; Gotesman et al., 2013; Hartman et al., 2008). In Brazil, virus-free breeding is an infrequent practice among ornamental fish farmers. It is believed that the diminished number of laboratories that perform viral disease diagnosis, and the lack of technical knowledge in the field related to the principal diseases that are caused by viruses contribute to the low importance given to this practice. It is likely that, because Brazil is “free from notifiable diseases” according to OIE, there is no legal requirement for sanitary substantiation in the breeding stock marketed.

The business establishments that commercialize aquatic animals must adopt good practices related to biosecurity, including disinfection of ponds after the last animals leave and the new ones arrive in the system; disinfection of utensils used for manipulation, which must be individual and exclusive for each system (Smail et al., 2004); and the treatment of the recirculation water with ultraviolet light and ozone filters, in addition to the training of the contributors to identify early stages of diseases.

Associated with the disease-free certification, it is essential that the commerce adopts quarantines between 15 to 90 days for entering animals, depending on the pathogen of interest and the function of the animal. During quarantine, it is recommended that blood exam surveys be conducted to detect animals that may be carriers of pathogens that can cause disease (Mcdermott & Palmeiro, 2013).

Nevertheless, there is no legal requirement for quarantine for fish created in the national territory, based on the premise

that Brazil is free of diseases of economic concern and on the lack of mandatory notification of illnesses. The effective sanitary control in Brazilian breeding stock can only be achieved with the adoption of biosecurity measures in all phases of the production system and commercialization of aquatic ornamental organisms.

Prevention and control for fungal diseases

The occurrence of fungi in water is directly related to its quality. Good practice in management must guarantee that there will not be an accumulation of organic matter in water and that stressful conditions will be minimized. Fungal infections are directly related to a drop in fish immunity, improper management, and low levels of water quality.

The treatment of water through ozonation and ultraviolet light filters are also efficient preventive measures. Ozone, in addition to breaking down organic matter present in the aquatic environment, can reduce the number of active zoospores that are potentially infective. In fingerling production, the water ozonation is capable of dramatically reducing the death of eggs caused by the presence of fungi (Powell et al., 2015).

Conflict of Interest

The authors state they have no conflicts of interest to declare.

Ethics Statement

Ethics Statement CEUA 4516111214

Acknowledgements

This study was financed in part by the Coordination of Improvement of Higher Education Personnel-Brazil (CAPES) - Finance Code 001. We thank the National Council for Scientific and Technological Development (CNPq) for doctoral scholarship to P. H. M. Cardoso (CNPq 160855/2014-4).

References

Abd El-Galil MAA, Mohamed MH. First Isolation of *Vibrio alginolyticus* from ornamental bird wrasse fish (*Gomphosus caeruleus*) of the Red Sea in Egypt. *Su Ürün Derg.* 2012;7(6):461-7. <http://dx.doi.org/10.3923/jfas.2012.461.467>.

ABINPET: Associação Brasileira da Indústria de Produtos Para Animais de Estimação [Internet]. Dados de Mercado.

São Paulo: ABINPET; 2017. [cited 2018 Dec 17]. Available from: <https://bit.ly/2R8Fdta>

Afzali SF, Mohd Daud HH, Sharifpour I, Afsharnasab M, Shankar S. Experimental infection of *Aphanomyces invadans* and susceptibility in seven species of tropical fish. *Vet World.* 2015;8(9):1038-1044. <http://dx.doi.org/10.14202/vetworld.2015.1038-1044>.

- Ahne W, Bjorklund HV, Essbauer S, Fijan N, Kurath G, Winton JR. Spring viremia of carp (SVC). *Dis Aquat Organ*. 2002;52:261-72. <http://dx.doi.org/10.3354/dao052261>.
- Alexandre FA, Faria JAF, Cardoso CF. Avaliação da eficiência da radiação ultravioleta na esterelização de embalagens plásticas. *Ciênc Agrotec*. 2008;32(5):1524-30. <http://dx.doi.org/10.1590/S1413-70542008000500025>.
- Alexandrino AC, Ranzani-Paiva MJT, Romano LA. Identificación de viremia primaveral de la carpa (VPC) *Carassius auratus* em San Pablo. *Rev Ceres*. 1998;45(258):125-37.
- Altun S, Gül Büyükekiz A, Duman M, Özgür Özyiğit M, Karatas S, Turgay E. Isolation of *Shewanella putrefaciens* from goldfish (*Carassius auratus auratus*). *Isr J Aquacult-Bamid*. 2014;66.
- Alves CBM, Vieira F, Magalhães ALB, Brito MF. Impacts on non-native fish species in Minas Gerais, Brazil: present situation and prospects. *Ecol Genet Implic Aquac Act*. 2007;6:291-314. https://doi.org/10.1007/978-1-4020-6148-6_16.
- Beaz-Hidalgo R, Agüeria D, Latif-Eugenín F, Yeannes MI, Figueras MJ. Molecular characterization of *Shewanella* and *Aeromonas* isolates associated with spoilage of Common carp (*Cyprinus carpio*). *FEMS Microbiol Lett*. 2015;362(1):1-8. <http://dx.doi.org/10.1093/femsle/fnu029>.
- Becker JA, Tweedie A, Rimmer A, Landos M, Lintermans M, Whittington RJ. Incursions of Cyprinid herpesvirus 2 in goldfish populations in Australia despite quarantine practices. *Aquaculture*. 2014;432:53-9. <http://dx.doi.org/10.1016/j.aquaculture.2014.04.020>.
- Beran V, Matlova L, Dvorska L, Svastova P, Pavlik I. Distribution of mycobacteria in clinically healthy ornamental fish and their aquarium environment. *J Fish Dis*. 2006;29(7):383-93. <http://dx.doi.org/10.1111/j.1365-2761.2006.00729.x>.
- Bizani D, Brandelli A. Antimicrobial susceptibility, hemolysis, and hemagglutination among *Aeromonas* spp. isolated from water of a bovine abattoir. *Braz J Microbiol*. 2001;32(4):334-339. <http://dx.doi.org/10.1590/S1517-83822001000400016>.
- Brasil. Ministério da Agricultura Pecuária e Abastecimento. Instrução Normativa nº 18, de 13 de maio de 2008. Estabelece os procedimentos para importação de animais aquáticos para fins ornamentais e destinados a comercialização Diário Oficial da União; Brasília; 2008a May 15.
- Brasil. Instituto Brasileiro do Meio Ambiente e dos Recursos Naturais Renováveis. Instrução Normativa nº 202, de 22 de outubro de 2008. Diário Oficial da União, Brasília; 2008b.
- Brasil. Instrução Normativa nº 6, de 19 de maio de 2011. Dispõe sobre o Registro e a Licença de Aquicultor. Diário Oficial da União; Brasília; 2011 May 20.
- Brasil. Ministério da Pesca e Aquicultura. Ministério do Estado do Meio Ambiente. Instrução Normativa Interministerial nº 1, de 3 de janeiro de 2012. Estabelece normas, critérios e padrões para a exploração de peixes nativos ou exóticos de águas continentais com finalidade ornamental ou de aquariofilia. Diário Oficial da União; Brasília; 2012 Jan 4.
- Bretzinger A, Fischer-Scherl T, Oumouna M, Hoffmann R, Truyen U. Mass mortalities in Koi carp, *Cyprinus carpio*, associated with gill and skin disease. *Bull Eur Assoc Fish Pathol*. 1999;19(5):182-5.
- Camus AC, Dill JA, Mcdermott AJ, Clauss TM, Berliner AL, Boylan SM, Soto E. *Francisella noatunensis* subsp. *orientalis* infection in Indo-Pacific reef fish entering the United States through the ornamental fish trade. *J Fish Dis*. 2013;36(7):681-4. <http://dx.doi.org/10.1111/jfd.12071>.
- Cardoso PHM, Balian SC. Lymphocystis vírus em peixes ornamentais importados para o Brasil. *Rev Educ Contin CRMV-SP*. 2016;14(1):6-11.
- Cardoso PHM, Balian SC, Maganha SRL, Souza RLM. First report of Megalocytivirus in red piranhas (*Pygocentrus nattereri*) by molecular diagnosis in Brazil. *Int J Avian & Wildlife Biol*. 2017a;2(3):2-4. <http://dx.doi.org/10.15406/ijawb.2017.02.00023>.
- Cardoso PHM, Balian SC, Matushima ER, Pádua SB, Martins ML. First report of scuticociliatosis caused by *Uronema* sp. in ornamental reef fish imported into Brazil. *Rev Bras Parasitol Vet*. 2017b;26(3):1-6. <http://dx.doi.org/10.1590/s1984-29612017031>.
- Cardoso PHM, Costa AR, Pestelli M, Balian SC. Relato de caso de parasitismo por Monogênea no peixe ornamental *Polypterus palmas* no Brasil. *Rev Educ Contin CRMV-SP*. 2017c;15(1):30-6.
- Chang PH, Lee SH, Chiang HC, Jong MH. Epizootic of herpes-like virus infection in goldfish, *Carassius auratus* in Taiwan. *Fish Pathol*. 1999;34(4):209-10. <http://dx.doi.org/10.3147/jsfp.34.209>.

- Chen YS, Liu YC, Yen MY, Wang JH, Wang JH, Wann SR, Cheng DL. Skin and soft-tissue manifestations of *Shewanella putrefaciens* infection. *Clin Infect Dis*. 1997;25(2):225-9.
- Cheung J, Fung B, Ip W, Chow SP. *Mycobacterium marinum* infection of the hand and wrist. *J Orthop Surg (Hong Kong)*. 2012;20(2):214-8. <http://dx.doi.org/10.1177/230949901202000216>.
- Citarasu T, Alfred Dhas K, Velmurugan S, Thanga Viji V, Kumaran T, Michael Babu M, Selvaraj T. Isolation of *Aeromonas hydrophila* from infected ornamental fish hatchery during massive outbreaks. *Int J Curr Res*. 2011;2(1):37-41.
- Colquhoun DJ, Duodu S. Francisella infections in farmed and wild aquatic organisms. *Vet Res*. 2011;42(1):7-15. <http://dx.doi.org/10.1186/1297-9716-42-47>.
- Crosby TC, Hill JE, Martinez CV, Watson CA, Pouder DB, Roy PE. On-Farm Transport of Ornamental Fish 1. IFAS Extension University of Florida. 2014;FA119:1-6.
- Davison AJ, Kurobe T, Gatherer D, Cunningham C, Korf I, Fukuda H, Hedrick RP. Comparative genomics of carp Herpesviruses. *J Virol*. 2013;87(5):2908-22. <http://dx.doi.org/10.1128/JVI.03206-12>.
- Declercq AM, Chiers K, Van Den Broeck W, Dewulf J, Eeckhaut V, Cornelissen M, Bossier P, Haesebrouck F, Decostere A. Interactions of highly and low virulent *Flavobacterium columnare* isolates with gill tissue in carp and rainbow trout. *Vet Res*. 2015;46(25):1-16. <http://dx.doi.org/10.1186/s13567-015-0164-5>.
- Declercq AM, Haesebrouck F, Van Den Broeck W, Bossier P, Decostere A. Columnaris disease in fish: a review with emphasis on bacterium-host interactions. *Vet Res*. 2013;44(1):27. <http://dx.doi.org/10.1186/1297-9716-44-27>.
- Dopazo CP, Bandín I. Patología viral de peces. In: Tavares-Dias, M. Manejo e sanidade de peixes em cultivo. Macapá: Embrapa Amapá; 2009. p. 495-531.
- Essa MAA, Kenawy AM, El-Gawad DMA. Epizootiological and histopathological studies on Mycobacteriosis in some ornamental fishes. *Glob Vet*. 2009;3(2):137-43.
- Essbauer S, Ahne W. Viruses of lower vertebrates. *J Vet Med B*. 2001;48(6):403-75. <http://dx.doi.org/10.1046/j.1439-0450.2001.00473.x>.
- FAO: Food and Agriculture Organization of the United Nations, GLOBEFISH - Analysis and Information on World Fish Trade [Internet]. Fish industry recognizing ornamental fish trade at the 2nd International Ornamental Fish Trade and Technical Conference. Rome: FAO; 2017 [cited 2019 Feb 5]. Available from: <http://www.fao.org/in-action/globefish/news-events/details-news/en/c/469648/>.
- Fulde M, Valentin-Weigand P. Epidemiology and pathogenicity of zoonotic streptococci. *Curr Top Microbiol Immunol*. 2013;368:49-81. http://dx.doi.org/10.1007/82_2012_277.
- Gaikowski MP, Larson WJ, Steuer JJ, Gingerich WH. Validation of two dilution models to predict chloramine-T concentrations in aquaculture facility effluent. *Aquacult Eng*. 2004;30(3-4):127-40. <http://dx.doi.org/10.1016/j.aquaeng.2003.11.001>.
- Gallani SU, Sebastião F. A., Valladão GMR, Boaratti AZ, Pilarski F. Pathogenesis of mixed infection by *Spiroplasma* sp. and *Citrobacter freundii* in freshwater angelfish *Pterophyllum scalare*. *Microb Pathog*. 2016;100:119-23. <http://dx.doi.org/10.1016/j.micpath.2016.09.002>.
- Garver KA, Al-Hussiney L, Hawley LM, Schroeder T, Edes S, Lepage V, Contador E, Russell S, Lord S, Stevenson RMW, Souter B, Wright E, Lumsden JS. Mass mortality associated with Koi Herpesvirus in wild common carp in Canada. *J Wildl Dis*. 2010;46:1242-51. <http://dx.doi.org/10.7589/0090-3558-46.4.1242>.
- Gauthier DT. Bacterial zoonoses of fishes: A review and appraisal of evidence for linkages between fish and human infections. *Vet J*. 2015;203(1):27-35. <http://dx.doi.org/10.1016/j.tvjl.2014.10.028>.
- Goodwin AE, Merry GE, Sadler J. Detection of the herpesviral hematopoietic necrosis disease agent (Cyprinid herpesvirus 2) in moribund and healthy goldfish: validation of a quantitative PCR diagnostic method. *Dis Aquat Organ*. 2006;69:137-43. <http://dx.doi.org/10.3354/dao069137>.
- Gotesman M, Kattlun J, Bergmann SM, El-Matbouli M. CyHV-3: the third Cyprinid herpesvirus. *Dis Aquat Organ*. 2013;105(2):163-74. <http://dx.doi.org/10.3354/dao02614>.
- Grim CJ, Kozlov EV, Sha J, Fitts EC, Van Lier CJ, Kirtley ML, Joseph SJ, Read TD, Burd EM, Tall BD, Joseph SW, Horneman AJ, Chopra AK, Shak JR. Characterization of *Aeromonas hydrophila* wound pathotypes by comparative genomic and functional analyses of virulence genes. *MBio*. 2013;4(2):1-13. <http://dx.doi.org/10.1128/mBio.00064-13>.

- Guerra IMF, Fadanelli R, Figueiró M, Schreiner F, Delamare APL, Wollheim C, Costa SOP, Echeverrigaray S. *Aeromonas* associated diarrhoeal disease in south Brazil: prevalence, virulence factors and antimicrobial resistance. *Braz J Microbiol.* 2007;38(4):638-43. <http://dx.doi.org/10.1590/S1517-83822007000400011>.
- Guz L, Puk K, Walczak N, Onisczuzuk T, Onisczuzuk A. Effect of dietary supplementation with *Echinacea purpurea* on vaccine efficacy against infection with *Flavobacterium columnare* in zebrafish (*Danio rerio*). *Pol J Vet Sci.* 2014;17(4):583-6. <http://dx.doi.org/10.2478/pjvs-2014-0087>.
- Hanson L, Dishon A, Kotler M. Herpesviruses that infect fish. *Viruses.* 2011;1:2160-91. <http://dx.doi.org/10.3390/v3112160>.
- Hartman KH, Yanong RPE, Pouder DB, Petty BD, Francis-Floyd R, Riggs AC. Koi herpesvirus (KHV) disease. *IFAS Extension.* 2008;VM149:1-9.
- Hashem M, El-Barbary M. *Vibrio harveyi* infection in Arabian Surgeon fish (*Acanthurus sohal*) of red sea at hurghada, Egypt. *Egyptian J Aquat Res.* 2013;39(3):199-203. <http://dx.doi.org/10.1016/j.ejar.2013.10.006>.
- Hawke JP, Kent M, Rogge M, Baumgartner W, Wiles J, Shelley J, Christine Savolainen L, Wagner R, Murray K, Peterson TS. Edwardsiellosis caused by *Edwardsiella ictaluri* in laboratory populations of Zebrafish *Danio rerio*. *J Aquat Anim Health.* 2013;25(3):171-83. <http://dx.doi.org/10.1080/08997659.2013.782226>.
- Hedrick RP, Gilad O, Yun S, Spangenberg JV, Marty GD, Nordhausen RW, Kebus MJ, Bercovier H, Eldar A. A Herpesvirus associated with mass mortality of juvenile and adult Koi, a strain of common carp. *J Aquat Anim Health.* 2000;12(1):44-57. [http://dx.doi.org/10.1577/1548-8667\(2000\)012<0044:AHAWMM>2.0.CO;2](http://dx.doi.org/10.1577/1548-8667(2000)012<0044:AHAWMM>2.0.CO;2).
- Hegde A, Teh HC, Lam TJ, Sin YM. Nodavirus infection in freshwater ornamental fish, guppy, *Poecilia reticulata* - comparative characterization and pathogenicity studies. *Arch Virol.* 2003;148(3):575-86. <http://dx.doi.org/10.1007/s00705-002-0936-x>.
- Hesami S, Viadanna P, Steckler N, Spears S, Thompson P, Yanong R, Francis-Floyd R, Shelley J, Groff J, Goodwin A, Waltzek T. Carp edema virus disease (CEVD) / Koi sleepy disease. *IFAS Extension.* 2015;FA189:1-6.
- Holt HM, Gahrn-Hansen B, Bruun B. *Shewanella* algae and *Shewanella putrefaciens*: clinical and microbiological characteristics. *Clin Microbiol Infect.* 2005;11(5):347-52. <http://dx.doi.org/10.1111/j.1469-0691.2005.01108.x>.
- Hossain M, Song J-Y, Kitamura S-I, Jung S-J, Oh M-J. Phylogenetic analysis of lymphocystis disease virus from tropical ornamental fish species based on a major capsid protein gene. *J Fish Dis.* 2008;31:473-9. <http://dx.doi.org/10.1111/j.1365-2761.2008.00917.x>.
- Humphrey JD, Lancaster C, Gudkovs N, McDonald W. Exotic bacterial pathogens *Edwardsiella tarda* and *Edwardsiella ictaluri* from imported ornamental fish *Betta splendens* and *Puntius conchonius*, respectively: isolation and quarantine significance. *Aust Vet J.* 1986;63:369-71. <http://dx.doi.org/10.1111/j.1751-0813.1986.tb02900.x>.
- Iberahim NA, Trusch F, Van West P. *Aphanomyces invadans*, the causal agent of Epizootic Ulcerative Syndrome, is a global threat to wild and farmed fish. *Fungal Biol Rev.* 2018;44(0):1-13. <http://dx.doi.org/10.1016/j.fbr.2018.05.002>.
- Janda JM. *Shewanella*: A marine pathogen as an emerging cause of human disease. *Clin Microbiol Newsl.* 2014;36(4):25-9. <http://dx.doi.org/10.1016/j.clinmicnews.2014.01.006>.
- Jeffery KR, Bateman K, Bayley A, Feist SW, Hulland J, Longshaw C, Stone D, Woolford G, Way K. Isolation of a cyprinid herpesvirus 2 from goldfish, *Carassius auratus* (L.), in the UK. *J Fish Dis.* 2007;30:649-56. <http://dx.doi.org/10.1111/j.1365-2761.2007.00847.x>.
- Jiang RHY, De Bruijn I, Haas BJ, Belmonte R, Löbach L, Christie J, Van Den Ackerveken G, Bottin A, Bulone V, Díaz-Moreno SM, Dumas B, Fan L, Gaulin E, Govers F, Grenville-Briggs LJ, Horner NR, Levin JZ, Mammella M, Meijer HJG, Morris P, Nusbaum C, Oome S, Phillips AJ, Van Rooyen D, Rzeszutek E, Saraiva M, Secombes CJ, Seidl MF, Snel B, Stassen JHM, Sykes S, Tripathy S, Van Den Berg H, Vega-Arreguin JC, Wawra S, Young SK, Zeng Q, Dieguez-Urbeondo J, Russ C, Tyler BM, Van West P. Distinctive expansion of potential virulence genes in the genome of the Oomycete fish pathogen *Saprolegnia parasitica*. *PLoS Genet.* 2013;9(6). <http://dx.doi.org/10.1371/journal.pgen.1003272>.
- Keawcharoen J, Techangamsuwan S, Ponpornpisit A, Lombardini ED. Genetic characterization of a betanodavirus isolated from a clinical disease outbreak in farm-raised tilapia *Oreochromis niloticus* (L.) in Thailand. *J Fish Dis.* 2015;38:49-54. <http://dx.doi.org/10.1111/jfd.12200>.

- Kent ML, Feist SW, Harper C, Hoogstraten-Miller S, Mac Law J, Sánchez-Morgado JM, Tanguay RL, Sanders GE, Spitsbergen JM, Whipps CM. Recommendations for control of pathogens and infectious diseases in fish research facilities. *Comp Biochem Physiol C Toxicol Pharmacol.* 2009;149(2):240-8. <http://dx.doi.org/10.1016/j.cbpc.2008.08.001>.
- Lehane L, Rawlin GT. Topically acquired bacterial zoonoses from fish: a review. *Med J Aust.* 2000;173(5):256-9.
- Lewis E, Dressler A, Saleh M. Francisellosis in ornamental African cichlids in Austria. *Bull Eur Assoc Fish Pathol.* 2014;34(2):63-70.
- Lincoln A, Magalhães B, Jacobi CM. Reprodução do peixe não-nativo barbo-rosado *Pethia conchonius* (Hamilton, 1822) (Pisces : Cyprinidae) na zona de amortecimento do Parque Estadual da Serra do Brigadeiro (PESB), Minas Gerais. *Biodiversidade Brasileira.* 2013;3(2):207-16.
- Lowry T, Smith SA. Aquatic zoonoses associated with food, bait, ornamental, and tropical fish. *J Am Vet Med Assoc.* 2007;231(6):876-80. <http://dx.doi.org/10.2460/javma.231.6.876>.
- Maganha SRL. Detecção e caracterização moleculares de vírus das famílias Alloherpesviridae e Iridoviridae em espécies de peixes ornamentais no Brasil [dissertação]. Pirassununga: Faculdade de Zootecnia e Engenharia de Alimentos, Universidade de São Paulo; 2016. 120 p. <http://dx.doi.org/10.11606/D.74.2016.tde-01112016-162605>.
- Majeed M, Kumar G, Schlosser S, El-Matbouli M, Saleh M. In vitro investigations on extracellular proteins secreted by *Aphanomyces invadans*, the causative agent of epizootic ulcerative syndrome. *Acta Vet Scand.* 2017;59(1):1-9. <http://dx.doi.org/10.1186/s13028-017-0347-3>.
- Martins M, Mourino JL, Fezer G, Buglione C No, Garcia P, Silva B, Jatobá A, Vieira F. Isolation and experimental infection with *Vibrio alginolyticus* in the sea horse, *Hippocampus reidi* Ginsburg, 1933 (Osteichthyes : Syngnathidae) in Brazil. *Braz J Biol.* 2010;70(1):205-9. <http://dx.doi.org/10.1590/S1519-69842010000100028>.
- Mcdermott C, Palmeiro B. Selected emerging infectious diseases of ornamental fish. *Vet Clin North Am Exot Anim Pract.* 2013;16(2):261-82. <http://dx.doi.org/10.1016/j.cvex.2013.01.006>.
- Nakajima K, Inouye K, Sorimachi M. Viral diseases in cultured marine fish in Japan. *Fish Pathol.* 1998;33:181-8.
- Nisha RG, Rajathi V, Manikandan R, Prabhu NM. Isolation of *Plesiomonas shigelloides* from infected cichlid fishes using 16S rRNA characterization and its control with probiotic *Pseudomonas* sp. *Acta Sci Vet.* 2014;42(1):1-7.
- Noga EJ. Fish disease: diagnosis and treatment. 2nd ed. USA: Willey-Blackwell; 2010. 536 p.
- Nolan D, Stephens F, Crockford M, Jones JB, Snow M. Detection and characterization of viruses of the genus *Megalocytivirus* in ornamental fish imported into an Australian border quarantine premises: an emerging risk to national biosecurity. *J Fish Dis.* 2015;38:187-95. <http://dx.doi.org/10.1111/jfd.12222>.
- OIE: The World Organisation for Animal Health. Aquatic Animal Health Code. 20th ed. Paris: OIE; 2017. Chapter 1.3, Diseases listed by the OIE; p. 7-8.
- Osman A, Ali E, Hashem M, Mostafa M, Mekawy I. Genotoxicity of two pathogenic strains of zoospore fungi (*Achlya klebsiana* and *Aphanomyces laevis*) on erythrocytes of Nile tilapia *Oreochromis niloticus niloticus*. *Ecotoxicol Environ Saf.* 2010;73(1):24-31. <http://dx.doi.org/10.1016/j.ecoenv.2009.08.021>.
- Park J, Kim P-K, Lim T, Daniels HV. Ozonation in seawater recirculating systems for black seabream *Acanthopagrus schlegelii* (Bleeker): effects on solids, bacteria, water clarity, and color. *Aquacult Eng.* 2013;55:1-8. <http://dx.doi.org/10.1016/j.aquaeng.2013.01.002>.
- Parker JL, Shaw JG. *Aeromonas* spp. clinical microbiology and disease. *J Infect.* 2011;62(2):109-18. <http://dx.doi.org/10.1016/j.jinf.2010.12.003>.
- Pate M, Jencic V, Zolnir-Dovc M, Ocepek M. Detection of mycobacteria in aquarium fish in Slovenia by culture and molecular methods. *Dis Aquat Organ.* 2005;64(1):29-35. <http://dx.doi.org/10.3354/dao064029>.
- Pękala A, Kozińska A, Paździor E, Głowacka H. Phenotypical and genotypical characterization of *Shewanella putrefaciens* strains isolated from diseased freshwater fish. *J Fish Dis.* 2015;38(3):283-93. <http://dx.doi.org/10.1111/jfd.12231>.
- Petty BD, Francis-Floyd R, Yanong RPE. Spring viremia of Carp. IFAS Extension. 2012;VM-142:1-5.

- Powell A, Chingombe P, Lupatsch I, Shields RJ, Lloyd R. The effect of ozone on water quality and survival of turbot (*Psetta maxima*) maintained in a recirculating aquaculture system. *Aquacult Eng.* 2015;64:20-4. <http://dx.doi.org/10.1016/j.aquaeng.2014.11.005>.
- Puk K, Banach T, Wawrzyniak A, Adaszek L, Ziętek J, Winiarczyk S, Guz L. Detection of *Mycobacterium marinum*, *M. peregrinum*, *M. fortuitum* and *M. abscessus* in aquarium fish. *J Fish Dis.* 2017;41(1):153-6. <http://dx.doi.org/10.1111/jfd.12666>.
- Rahmati-Holasoo H, Hobbenaghi R, Tukmechi A, Seyrafi R, Homayounimehr A, Ghavami R. Lymphocystis in a flower horn fish. *Comp Clin Pathol.* 2010;19(4):433-5. <http://dx.doi.org/10.1007/s00580-010-0993-6>.
- Roberts HE, Palmeiro B, Weber ES. Bacterial and parasitic diseases of pet fish. *Vet Clin North Am Exot Anim Pract.* 2009;12(3):609-38. <http://dx.doi.org/10.1016/j.cvex.2009.06.010>.
- Russo R, Mitchell H, Yanong RPE. Characterization of *Streptococcus iniae* isolated from ornamental cyprinid fishes and development of challenge models. *Aquaculture.* 2006;256(1-4):105-10. <http://dx.doi.org/10.1016/j.aquaculture.2006.02.046>.
- Sano N, Moriwake M, Hondo R, Sano T. Herpesvirus cyprini: a search for viral genome in infected fish by infected fish by in situ hybridization. *J Fish Dis.* 1993;16:495-9. <http://dx.doi.org/10.1111/j.1365-2761.1993.tb00883.x>.
- Sano T, Fukuda H, Furukawa M. Herpesvirus cyprini: biological and oncogenic properties. *Fish Pathol.* 1985;20:381-8. <http://dx.doi.org/10.3147/jsfp.20.381>.
- Sano T, Morita N, Shima N, Akimoto M. A preliminary report on pathogenicity and oncogenicity of cyprinid herpesvirus. *Bull Eur Assoc Fish Pathol.* 1990;10(1):11-3.
- Sharrer MJ, Summerfelt ST. Ozonation followed by ultraviolet irradiation provides effective bacteria inactivation in a freshwater recirculating system. *Aquacult Eng.* 2007;37(2):180-91. <http://dx.doi.org/10.1016/j.aquaeng.2007.05.001>.
- Shetty M, Maiti B, Shivakumar K. Betanodavirus of Marine and Freshwater Fish : Distribution, Genomic Organization, Diagnosis and Control Measures. *Indian J Virol.* 2012;23(2):114-23. <http://dx.doi.org/10.1007/s13337-012-0088-x>.
- Sirmalaisyuan A, Teeraruk P, Kanjanapitakchai P, Kaewsakhorn T, Potibut P, Pikulkaew S. Detection of *Mycobacterium marinum* in clinically asymptomatic Siamese fighting fish (*Betta splendens*) from ornamental fish shops in Chiang Mai Province, Thailand. *Asian Pac J Trop Dis.* 2016;6(8):344-6. <http://dx.doi.org/10.12980/apjtd.7.2017D6-446>.
- Smail DA, Grant R, Simpson D, Bain N, Hastings TS. Disinfectants against cultured Infectious Salmon Anaemia (ISA) virus: the virucidal effect of three iodophors, chloramine T, chlorine dioxide and peracetic acid/hydrogen peroxide/acetic acid mixture. *Aquaculture.* 2004;240(1-4):29-38. <http://dx.doi.org/10.1016/j.aquaculture.2004.05.045>.
- Sreedharan K, Philip R, Singh ISB. Isolation and characterization of virulent *Aeromonas veronii* from ascitic fluid of oscar *Astronotus ocellatus* showing signs of infectious dropsy. *Dis Aquat Organ.* 2011;94(1):29-39. <http://dx.doi.org/10.3354/dao02304>.
- Stephens F, Raidal S, Jones B. Haematopoietic necrosis in a goldfish (*Carassius auratus*) associated with an agent morphologically similar to herpesvirus. *Aust Vet J.* 2004;82(3):167-69. <https://doi.org/10.1111/j.1751-0813.2004.tb12650.x>.
- Summerfelt ST. Ozonation and UV irradiation - An introduction and examples of current applications. *Aquacultural Engineering.* 2002;28(1-2):21-36. [https://doi.org/10.1016/S0144-8609\(02\)00069-9](https://doi.org/10.1016/S0144-8609(02)00069-9).
- Suzuki M, Suzuki S, Matsui M, Hiraki Y, Kawano F, Shibayama K. Genome sequence of a strain of the human pathogenic bacterium *Pseudomonas alcaligenes* that caused bloodstream infection. *Genome Announc.* 2013;1(5):1-2. <https://doi.org/10.1128/genomeA.00919-13>.
- Tendencia EA. The first report of *Vibrio harveyi* infection in the sea horse *Hippocampus kuda* Bleekers 1852 in the Philippines. *Aquacult Res.* 2004;35(13):1292-4. <http://dx.doi.org/10.1111/j.1365-2109.2004.01109.x>.
- Tukmechi A, Hobbenaghi R, Rahmati Holasoo H, Morvaridi A. Streptococcosis in a pet fish, *Astronotus ocellatus*: A case study. *Int J Biol Sci.* 2009;1(1):30-1.
- Van West P. *Saprolegnia parasitica*, an oomycete pathogen with a fishy appetite: new challenges for an old problem. *Mycologist.* 2006;20(3):99-104. <http://dx.doi.org/10.1016/j.mycol.2006.06.004>.

- Verma D, Rathore G, Pradhan PK, Sood N, Punia P. Isolation and characterization of *Flavobacterium columnare* from freshwater ornamental goldfish *Carassius auratus*. *J Environ Biol.* 2015;36(2):433-9.
- Viadanna PHO, Pilarski F, Hesami S, Waltzek TB. First report of Carp Edema Virus (CEV) in South American Koi. In: Proceedings of the 40th Eastern Fish Health Workshop; 2015 Mar 2-6; Charleston, SC. Mt. Pleasant (SC): EFHW; 2015.
- Volpe E, Grodzki M, Panzarin V, Guercio A, Purpari G, Serratore P, Ciulli S. Detection and molecular characterization of betanodaviruses retrieved from bivalve molluscs. *J Fish Dis.* 2017;41(4):603-11. <http://dx.doi.org/10.1111/jfd.12759>.
- Way K, Haenen O, Stone D, Adamek M, Bergmann SM, Bigarré L, Diserens N, Gjessing MC, Leguay E, Matras M, Olesen NJ, Panzarin V, Piac V. Emergence of carp edema virus (CEV) and its significance to European common carp and koi *Cyprinus carpio*. *Dis Aquat Organ.* 2017;126:155-66. <http://dx.doi.org/10.3354/dao03164>.
- Weir M, Rajić A, Dutil L, Cernicchiaro N, Uhland FC, Mercier B, Tuševljak N. Zoonotic bacteria, antimicrobial use and antimicrobial resistance in ornamental fish: a systematic review of the existing research and survey of aquaculture-allied professionals. *Epidemiol Infect.* 2012;140(2):192-206. <http://dx.doi.org/10.1017/S0950268811001798>.
- Whipps CM, Lieggi C, Wagner R. Mycobacteriosis in zebrafish colonies. *ILARJ.* 2012;53(2):95-105. <http://dx.doi.org/10.1093/ilar.53.2.95>.
- Whittington RJ, Becker JA, Dennis MM. Iridovirus infections in finfish - critical review with emphasis on ranaviruses. *J Fish Dis.* 2010;33:95-122. <http://dx.doi.org/10.1111/j.1365-2761.2009.01110.x>.
- Whittington RJ, Chong R. Global trade in ornamental fish from an Australian perspective: the case for revised import risk analysis and management strategies. *Prev Vet Med.* 2007;81(1-3):92-116. <http://dx.doi.org/10.1016/j.prevetmed.2007.04.007>.
- Wu T-S, Chiu C-H, Yang C-H, Leu H-S, Huang C-T, Chen Y-C, Wu T-L, Chang P-Y, Su L-H, Kuo A-J, Chia J-H, Lu C-C, Lai H-C. Fish tank granuloma caused by *Mycobacterium marinum*. *PLoS One.* 2012;7(7):e41296. <http://dx.doi.org/10.1371/journal.pone.0041296>.
- Xu L, Feng J, Huang Y. Identification of lymphocystis disease virus from paradise fish *Macropodus opercularis* (LCDV-PF). *Arch Virol.* 2014; 159(9):2445-2449 <http://dx.doi.org/10.1007/s00705-014-2060-0>.
- Yanong RPE. Lymphocystis disease in fish. *IFAS Extension.* 2013;FA181:1-4.
- Yanong RPE, Pouder DB. Association of Mycobacteria in Recirculating Aquaculture Systems and Mycobacterial Disease in Fish. *J Aquat Anim Health.* 2010;22(4):219-23. <http://dx.doi.org/10.1577/H10-009.1>.
- Yanong RPE, Waltzek TB. Megalocytivirus infections in fish, with emphasis on ornamental species. *IFAS Extension.* 2011;FA182:1-7.
- Yong CY, Yeap SK, Omar AR, Tan WS. Advances in the study of nodavirus. *PeerJ.* 2017;5(5):1-31. <http://dx.doi.org/10.7717/peerj.3841>.
- Yucel N, Aslim B, Beyatli Y. Prevalence and resistance to antibiotics for *Aeromonas* species isolated from retail fish in Turkey. *J Food Qual.* 2005;28(4):313-24. <http://dx.doi.org/10.1111/j.1745-4557.2005.00037.x>.

Financial Support: Coordination of Improvement of Higher Education Personnel-Brazil (CAPES) - Finance Code 001

Authors Contributions: Pedro Henrique Magalhães Cardoso participated in the planning, execution and confection of the manuscript. Andrea Micke Moreno participated in execution and revision of the manuscript. Luisa Zanolli Moreno participated in execution and revision of the manuscript. Carolina Helena de Oliveira participated in execution of the manuscript. Francisco de Assis Baroni participated in execution and revision of the manuscript. Samara Rita de Lucca Maganha participated in execution of the manuscript. Ricardo Luiz Moro de Sousa participated in execution and revision of the manuscript. Simone de Carvalho Balian participated in the planning, execution and confection of the manuscript.