

Protective effect of mulberry flavonoids on sciatic nerve in alloxan-induced diabetic rats

Song-Tao Ma*, Dong-lian Liu, Jing-jing Deng, Yan-juan Peng

Department of Pharmacy, Chengdu Medical College, Chengdu, China

Mulberry leaves (*Morus alba* L.) are a traditional Chinese medicine for blood serum glucose reduction. This study evaluated the protective effects of mulberry flavonoids on sciatic nerve in alloxan-induced diabetic rats. In this study, 80 Sprague-Dawley rats were divided into five groups: A (control), B (diabetic treated with saline), C-D (diabetic treated with 0.3, 0.1 g/kg mulberry flavonoids once a day for 8 weeks) and E (diabetic treated with 0.3 mg/kg methycobal). The diabetic condition was induced by intraperitoneal injection of 200 mg/kg alloxan dissolved in saline. At the end of the experimental period, blood, and tissue samples were obtained for biochemical and histopathological investigation. Treatment with 0.3 g/kg mulberry flavonoids significantly inhibited the elevated serum glucose ($P < 0.01$). The increased myelin sheath area ($P < 0.01$), myelinated fiber cross-sectional area and extramedullary fiber number ($P < 0.05$) were also reduced in alloxan-induced rats treated with 0.3 g/kg mulberry flavonoids. 0.3 g/kg mulberry flavonoids also markedly decreased onion-bulb type myelin destruction and degenerative changes of mitochondria and Schwann cells. These findings demonstrate that mulberry flavonoids may improve the recovery of a severe peripheral nerve injury in alloxan-induced diabetic rats and is likely to be useful as a potential treatment on peripheral neuropathy (PN) in diabetic rats.

Uniterms: *Morus alba* L./pharmacognosy. Mulberry flavonoids/protective effects/experimental study. Diabetic neuropathy/experimental study. Medicinal plants. Diabetics/treatment/experimental study.

Folhas de amoreira (*Morus alba* L.) é um medicamento tradicional chinês para a redução da glicose no soro sanguíneo. Avaliaram-se, neste trabalho, os efeitos protetores dos flavonóides de amora no nervo ciático em ratos diabéticos aloxano-induzidos. Dividiram-se 80 ratos Sprague-Dawley em cinco grupos: A (controle), B (diabéticos tratados com solução salina), C-D (diabéticos tratados com 0,3, 0,1 g/kg) e E (diabéticos tratados com 0,3 mg de metilcobal). A diabetes foi induzida por injeção intraperitoneal de 200 mg/kg de aloxana dissolvida em solução salina. No final do período experimental, obtiveram-se amostras de sangue e de tecido para investigação bioquímica e histopatológica. O tratamento com 0,3 g/kg de flavonóides da amoreira inibiu, significativamente, a elevação de glicose no soro ($p < 0,01$). O aumento da área da bainha de mielina ($p < 0,01$), da área de fibra da seção transversal e do número de fibras mielinizadas extramedulares ($p < 0,05$) foi também reduzido em ratos aloxânicos, tratados com 0,3 g/kg flavonóides de amora. Flavonóides da amoreira na dose de 0,3 g/kg também diminuíram, acentuadamente, a destruição da mielina do tipo bulbo de cebola e as alterações degenerativas das células mitocôndrias e das células de Schwann. Estes resultados demonstram que os flavonóides da amoreira podem melhorar a recuperação de uma lesão nervosa periférica grave em ratos com diabetes, induzida por aloxana, e parece ser útil como tratamento potencial para a neuropatia periférica (PN) em ratos diabéticos.

Unitermos: *Morus alba* L./farmacognosia. Flavonóides de amora/efeitos protetores/estudo experimental. Neuropatia diabética/estudo experimental. Plantas medicinais. Diabetes/tratamento/estudo experimental.

INTRODUCTION

Diabetes mellitus (DM) is a major degenerative ailment in the world today, affecting at least 100 million people in China (Hu, Zhang, 2011) and resulting in severe metabolic imbalances and pathological changes in many tissues. Diabetic peripheral neuropathy (DPN) is one of the most common secondary complications of diabetes, which affects approximately 70-90% of the world's population suffering from diabetes (Cow, 1997). The histopathology of the condition is characterized by axonal degeneration, demyelination, and atrophy in association with failed axonal regeneration, remyelination, and impaired synaptogenesis (Omran, 2012). Glucose control may prevent, stabilize, and even reverse neuropathy and other chronic diabetic complications (Ismail-Beigi *et al.*, 2010). Unfortunately, insulin therapy does not prevent the progression of chronic lesions in the nerves of the diabetic patient (Dandona *et al.*, 1985). Therefore, there is great interest in investigating other medicines to protect the peripheral nerves from damage.

In traditional Chinese medicine, several medicinal plants or their extracts are widely used to cure "Xiao-ke" (diabetes) such as Mulberry leaves (*Morus alba* L.). Mulberry tree is widely grown throughout China. The extract from Mulberry leaves (*Morus alba* L.), especially flavonoids, has been demonstrated to have potential effect on oxidative stress (Naowaboot *et al.*, 2009a), inflammation (Kim *et al.*, 2012) and cardiovascular protection (Naowaboot *et al.*, 2009b). Importantly, there has been scientific evidence showing that mulberry flavonoids has antihyperglycemic effects on patients with type 2 diabetes or diabetic animal model (Andallu, Varadacharyulu, 2002; Katsube *et al.*, 2010) and protective effects on ocular functions of pups of diabetic rats (El-Sayyad *et al.*, 2011). However, to date there has not been a study to assess the role of mulberry flavonoids on diabetic peripheral neuropathy.

Since Mulberry leaf is a potent natural blood glucose lowering activity agent, it was hypothesized that it has a neuroprotective role on sciatic nerve in diabetic rats. Hence, this investigation was conducted to examine whether mulberry flavonoids may counteract the effects of alloxan on peripheral neuropathy, specifically sciatic nerve damage. To the best of our knowledge, this research is the first report on the effects of mulberry flavonoids on sciatic nerve in alloxan-induced diabetic rats, which may contribute to the development of new phytotherapies in counteracting peripheral neuropathy of diabetes.

MATERIAL AND METHODS

Drug and Animals

The dried Mulberry leaves were collected in Chengdu, the provincial capital of Sichuan province, in China. Mulberry flavonoids (purity>98% by HPLC, No. 100601) was extracted from dried Mulberry leaf by Chengdu Yiquan Science and Technology Development Co., Ltd. (Chengdu, China). Methycobal pill (No. 101271A) was manufactured by Eisai Co., Ltd (Japan).

7-8 weeks Sprague-Dawley rats (male, n=40; female, n=40, respectively) weighing 180-220 g were purchased from the Experimental Animal Center of Chengdu University of Traditional Chinese Medicine (Chengdu, China). Animals were allowed free access to standard diet and sterile water in a restricted access room with temperature-controlled (20±1 °C) and humidity-controlled (60±10%) rooms under 12 h light/dark. All the experimental procedures were performed in accordance with the guidelines of the Experimental Research Institute of Chengdu University of Traditional Chinese Medicine. Forty rats were included in this study after confirmation of success of diabetic models and randomly divided into 5 groups: A (control), B (diabetic treated with saline), C (diabetic treated with 0.3 g/kg mulberry flavonoids, equivalent to 15 times of an adult human dosage), D (diabetic treated with 0.1 g/kg mulberry flavonoids, equivalent to 5 times of an adult human dosage) and E (diabetic treated with 0.3 mg/kg methycobal, equivalent to 10 times of an adult human dosage); each group contain ten animals.

Induction of diabetes

Diabetes rat model was induced in B-E group by intraperitoneal injection of alloxan dissolved in saline at the dose of 100 mg/kg body weight, twice a day. Control rats were injected with the same volume of saline as the diabetic animals that received alloxan. The serum glucose levels of each of the rats were checked everyday from the 3rd day with glucose oxidase method. After 5 days, animals with serum glucose levels of 16.7 mmol/L and above were considered to be diabetic and were used for the study. Serum glucose levels in control animals remained normal for the duration of the study.

The rats in B-E groups were given corresponding drug once a day orally for 8 weeks starting 5 days after alloxan injection, respectively. Control rats were given the same volume of saline once a day orally for 8 weeks. The initial and final body weight changes of the various

groups were recorded. Blood samples were collected by orbital venous and the initial and final serum glucose levels of the various groups were measured by glucose oxidase method. Segments of the right sciatic nerve were obtained from each rat after anaesthetized with 4% pentobarbital (25 mg/kg, i.p) and used for light and electron microscopy.

Histopathological examination

Sciatic nerve was fixed in 10% (v/v) neutral-buffered formalin for 24 h at 4 °C. Tissues were embedded in paraffin, sectioned at 4 µm thickness, and stained with chromotrope 2R-brilliant green solution. In the sciatic nerve, the myelin sheath area, myelinated fiber cross-sectional area and extramedullary fiber area were quantified using MIAS2000 software.

Electron microscopy

For electron microscopy, sciatic nerves specimens were fixed with 3% glutaraldehyde in 0.1 M sodium phosphate buffer (pH 7.2) for 3 h at 4 °C, washed in the same buffer for 1h at 4 °C and post-fixed with 1% osmium tetroxide in sodium phosphate buffer for 1h at 4 °C. The tissues were then dehydrated in graded series of acetone and embedded in Epon812. Ultrathin sections (60 nm) were stained with both lead citrate and uranyl acetate for the transmission electron microscope (H-600IV, Japan) evaluation. Seven different images from each specimen were taken to calculate myelinated fibre area and density using an image analysis system (Image-Pro Plus 6.1, Media Cybernetics, Silver Spring, MD, USA). The investigator was blind to group identity during the morphometry process.

Statistical analysis

Values are presented as means ± standard deviation. Statistical significance was determined by one-way

ANOVA and Student's t-test using SPSS13.0 for Windows. P<0.05 was considered to indicate statistical significance.

RESULTS

Effect of mulberry flavonoids on blood glucose level and body weight in diabetic rats

Blood glucose level and body weight were shown in Table I. The baseline weights of the rats at the beginning of the study were similar in all groups. The diabetic animals exhibited obviously decreased body weight and consistently hyperglycaemia relative to non-diabetic controls (P<0.01) (Table I). Treatment with 0.3g/kg mulberry flavonoids caused a visible decrease in the elevated serum glucose (P<0.05) in alloxan induced diabetic rats and a significantly difference in weight gain compared to the model group (P<0.01) (Table I).

Effects of mulberry flavonoids on morphological changes of myelinated fiber of sciatic nerve

The myelin sheath area and myelinated fiber cross-sectional area were decreased in diabetic rats (group B) compared with control rats (group A) and these changes were alleviated by mulberry flavonoids (group C, D) and methycobal (group E). Likewise, the average optical density of myelin sheath area and myelinated fiber cross-sectional area were decreased in diabetic rats (group B) compared with control rats (group A) and these changes were also alleviated by mulberry flavonoids and methycobal administration (P<0.05 or 0.01; Table II).

Effects of mulberry flavonoids on extramedullary fiber of sciatic nerve

In control rats, histology of sciatic nerves was normal (Figure 1A). The extramedullary fiber number in diabetic rats was significantly less than in control rats

TABLE I - Changes of rats' fasting blood glucose (FBG) and body Weight (BW) before/after the 8 weeks treatment ($\bar{x} \pm s$, n=10)

Group	Dosage (mg/kg)	FBG (mmol/L)		BW (g)	
		before	after	before	after
Control (A)	—	5.54±1.10	6.01±1.13	182.64±12.18	391.3±11.2
Diabetic model (B)	—	22.51±2.36**	19.86±3.89**	195.87±5.46	286.5±34.5**
Mulberry flavonoids (C)	300	21.67±2.32**	16.01±2.41** [△]	194.45±4.41	358.7±36.2** ^{#△△▲}
Mulberry flavonoids (D)	100	22.30±3.10**	18.12±2.65**	190.12±9.85	319.4±41.3**
Methycobal (E)	0.3	21.82±3.69**	18.35±3.10**	194.68±7.76	322.7±35.2**

*P<0.05, **P<0.01 vs group A; [△]P<0.05, ^{△△}P<0.01 vs group B; [▲]P<0.05 vs group D; [#]P<0.05, ^{##}P<0.01 vs group E

TABLE II - Changes of the myelin sheath area and myelinated fiber cross-sectional area of rat's sciatic nerve ($\bar{x} \pm s$, n=10)

Group	Dosage (mg/kg)	myelin sheath area (μm)	AOD of myelin sheath area	myelinated fiber cross-sectional area (μm)	AOD of myelinated fiber cross-sectional area
Control (A)	—	87.70 \pm 13.53	181.74 \pm 13.80	4311.09 \pm 975.53	288.45 \pm 29.10
Diabetic model (B)	—	60.43 \pm 8.34**	152.38 \pm 8.59**	2387.08 \pm 1101.25**	192.38 \pm 17.59**
Mulberry flavonoids (C)	300	82.36 \pm 5.01 $\Delta\Delta$	178.92 \pm 11.66 $\Delta\Delta$	3776.58 \pm 885.45 Δ	260.91 \pm 22.54* $\#\Delta\Delta$
Mulberry flavonoids (D)	100	77.45 \pm 7.64 $\Delta\Delta$	168.42 \pm 11.45 Δ	3418.23 \pm 976.56 Δ	240.85 \pm 18.34* $\Delta\Delta$
Methycobal (E)	0.3	71.49 \pm 9.03* Δ	168.31 \pm 8.22 Δ	3015.12 \pm 897.24* Δ	230.31 \pm 18.56** $\Delta\Delta$

*P<0.05, **P<0.01 vs group A; Δ P<0.05, $\Delta\Delta$ P<0.01 vs group B; # P<0.05, ## P<0.01 vs group E

(Figure 1B), whereas the numbers of extramedullary fiber of sciatic nerves were markedly increased in group C-E (Figures 1C, 1D and 1E), especially mulberry flavonoids treated groups (Figure 1C). The same results can be obtained by quantified using MIAS2000 software. In diabetic rats, the extramedullary fiber area and AOD were significantly reduced compared with control rats. Treated with mulberry flavonoids and methycobal can alleviate these changes (P < 0.05 or 0.01; Table III).

Effects of mulberry flavonoids on changes of ultrastructural of sciatic nerve

Ultrastructural evaluation of sciatic nerves confirmed the light microscopy findings. The sciatic nerves in control group showed normal structure (Figure 2A). Sciatic nerve electron micrograph of diabetic rats shows shrunken axons, myelin destructions with onion-bulb form protrusion on the myelin sheath

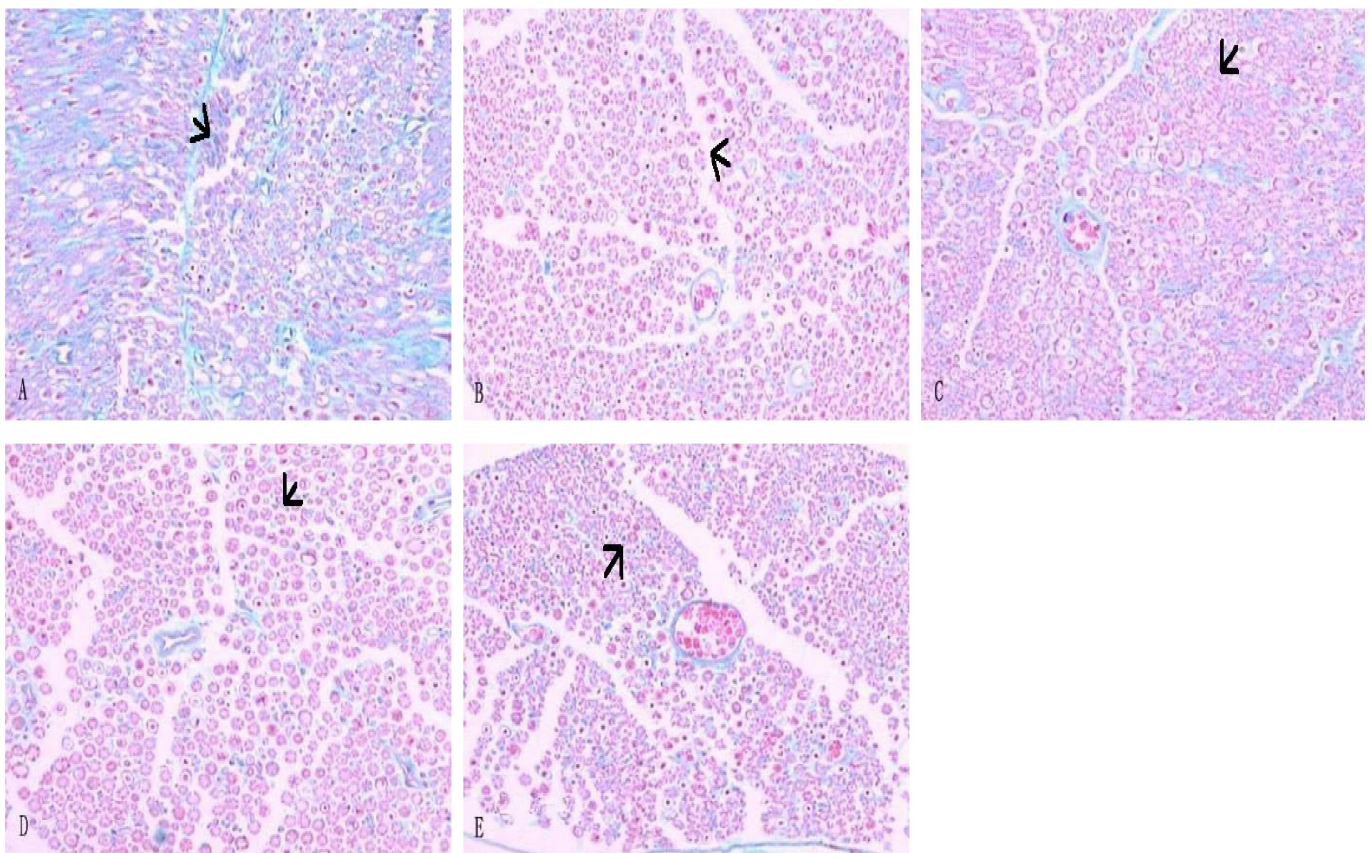


FIGURE 1 - Histology of the sciatic nerve of each experimental rat by staining with chromotrope 2R-brilliant green ($\times 200$) (A) Control rats. (B) Diabetic neuropathy rats. (C) Diabetic neuropathy rats treated with 0.3 g/kg mulberry flavonoids. (D) Diabetic neuropathy rats treated with 0.1 g/kg mulberry flavonoids. (E) Diabetic neuropathy rats treated with methycobal.

TABLE III - Change of extramedullary fiber of rat's sciatic nerve ($\bar{x} \pm s$, n=10)

Group	Dosage (mg/kg)	Area (μm)	AOD
Control (A)	—	78.69 \pm 7.53	188.21 \pm 9.30
Diabetic model (B)	—	56.41 \pm 10.25**	152.38 \pm 7.59**
Mulberry flavonoids (C)	300	69.36 \pm 7.11 ^{#Δ}	178.92 \pm 11.66 ^{$\Delta\Delta$}
Mulberry flavonoids (D)	100	63.24 \pm 8.64*	170.12 \pm 8.45 ^{Δ}
Methycobal (E)	0.3	66.54 \pm 7.03*	167.31 \pm 8.54 ^{Δ}

*P<0.05, **P<0.01 vs group A; ^{Δ} P<0.05, ^{$\Delta\Delta$} P<0.01 vs group B; #P<0.05, ## P<0.01 vs group E

and the axonal myelins were vacuolization and lamellar separation. Degenerative changes were also observed in mitochondria and Schwann cells (Figure 2B). Histologic evaluation of the tissues in animals pretreated with 0.3 g/kg mulberry flavonoids showed ultrastructural features of myelin and axons remarkable improved and myelin breakdown decreased markedly (Figure 2C). Likewise, vacuolization and lamellar separation of the

axonal myelin was less obvious. The fine structure of Schwann cells was seemingly normal.

DISCUSSION

The present study is the first to demonstrate that mulberry flavonoids had potent neuroprotective effects on sciatic nerve in alloxan-induced diabetic rat model, which

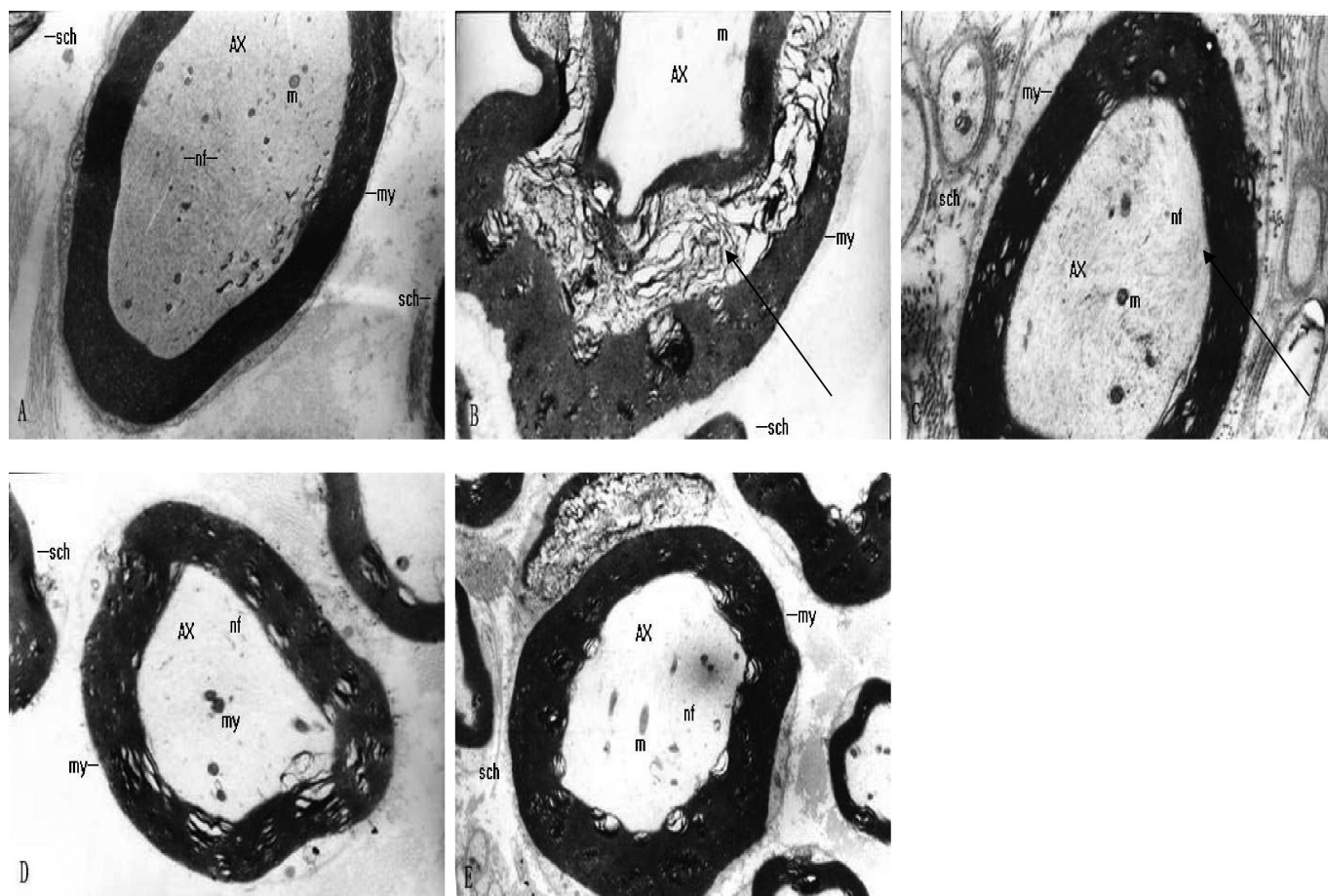


FIGURE 2 - Representative transmission electron micrographs showing the ultrastructure of sciatic nerves ($\times 7000$) (A) Control rats: intact myelinated axon. (B) Diabetic neuropathy rats: serious demyelination. (C) Diabetic neuropathy rats treated with 0.3 g/kg mulberry flavonoids: tiny segmental demyelination and local axon separation from sheaths is seen. (D) Diabetic neuropathy rats treated with 0.1 g/kg mulberry flavonoids: mild axon separation from the sheaths is seen. (E) Diabetic neuropathy rats treated with methycobal: mild axon separation from the sheaths is seen.

led to improvement of myelinated fiber and extramedullary fiber. Ultrastructural evaluation of sciatic nerves confirmed that mulberry flavonoids restored the axonal degeneration and demyelination.

Alloxan is one of the usual substances used to induce diabetes mellitus. It caused pancreatic β cells sufficient damage thus resulted to a notable increase in blood glucose levels (Verma *et al.*, 2010). In our study, we first evaluated the antidiabetic activity of mulberry flavonoids in alloxan-induced diabetic rats by testing fasting blood glucose level by glucose oxidase method. Our findings, in accordance with earlier studies, indicate that treatment with 0.3 g/kg mulberry flavonoids (equal to 15-fold the clinic dosage) significantly inhibit the alloxan-induced hyperglycemia of rats. On the other hand, our results also indicated that 0.3 g/kg mulberry flavonoids caused a significantly difference in weight gain compared to the model group.

As the most common secondary complications of diabetes, DPN is characterized by progressive axons loss in humans (Calcutt, Backonja, 2007). Axon demyelination and loss were also presented in the sciatic nerve of diabetic mice by electron microscopy examination (Kang *et al.*, 2011). The proper function and maintenance of axons depended on myelin formation (Lappe-Siefke *et al.*, 2003). Consequently, myelin loss results in pathological conditions, such as DPN. Moreover, the axon degeneration is relation with pathogenesis of negative signs of DPN (Thomas, 1999). As reported before (Veiga *et al.*, 2006), the most abundant nerve abnormality observed in our study was that both myelinated fiber and extramedullary fiber of the sciatic nerve were markedly decreased in diabetic rats, as opposed to the control group.

Flavonoids extracted from Mulberry leaves (*Morus alba* L.) were described for anti-diabetes effects in rats (Singab *et al.*, 2005) and demonstrated marked intestinal maltase inhibitory activity (Adisakwattana *et al.*, 2012) in vitro. In this study, we further evaluated the role of mulberry flavonoids on diabetic peripheral neuropathy in rat, and our morphological study of sciatic nerve revealed that administration of mulberry flavonoids, especially at the dose of 0.3 g/kg, notably increased the area of myelinated fiber and number of extramedullary fiber to close to the control group. Schwann cells, which are susceptible to hyperglycemia, play a crucial role in maintenance of peripheral nerve myelin. The sciatic nerve electron micrograph of diabetic rats in the present result shows degenerative changes of Schwann cells, onion-bulb type myelin destructions and lamellar separation. With 0.3 g/kg mulberry flavonoids treatment, the axonal

and Schwann cells degeneration were ameliorated, too.

In conclusion, we show that 0.3 g/kg mulberry flavonoids exert a substantial protective effect against alloxan-induced diabetic neuropathy in sciatic nerve of rats. These findings provide a therapeutic potential for future treatment of diabetic peripheral neuropathy.

ACKNOWLEDGEMENTS

This study was supported by Scientific Research Fund of Sichuan Provincial Traditional Chinese Medicine (No. 2008-05).

REFERENCES

- ADISAKWATTANA, S.; RUENG SAMRAN, T.; KAMPA, P.; SOMPONG, W. In vitro inhibitory effects of plant-based foods and their combinations on intestinal α -glucosidase and pancreatic α -amylase. *BMC Complement. Altern. Med.*, v.12, p.110, 2012.
- ANDALLU, B.; VARADACHARYULU, N.C.H. Control of hyperglycemia and retardation of cataract by mulberry (*Morus indica* L.) leaves in streptozotocin diabetic rats. *Indian J. Exp. Biol.*, v.40, p.791-795, 2002.
- CALCUTT, N.A.; BACKONJA, M.M. Pathogenesis of pain in peripheral diabetic neuropathy. *Curr. Diab. Rep.*, v.7, p.429-434, 2007.
- COW, A.P. The roles of oxidative stress and antioxidant treatment in experimental diabetic neuropathy. *Diabetes*, v.46, suppl.2, p.38-40, 1997.
- DANDONA, P.; BOLGER, J.P.; BOAG, F.; FONESCA, V.; ABRAMS, J.D. Rapid development and progression of proliferative retinopathy after strict diabetic control. *Br. Med. J. (Clin. Res. Ed.)*, v.290, p.895-896, 1985.
- EL-SAYYAD, H.I.; EL-SHERBINY, M.A.; SOBH, M.A.; ABOU-EL-NAGA, A.M.; IBRAHIM, M.A.; MOUSA, S.A. Protective effects of *Morus alba* leaves extract on ocular functions of pups from diabetic and hypercholesterolemic mother rats. *Int. J. Biol. Sci.*, v.7, p.715-728, 2011.
- HU, J.; ZHANG, X.E. Impact of epidemic rates of diabetes on the Chinese blood glucose testing market. *J. Diabetes Sci. Technol.*, v.5, p.1294-1299, 2011.

- ISMAIL-BEIGI, F.; CRAVEN, T.; BANERJI, M.A.; BASILE, J.; CALLES, J.; COHEN, R.M.; CUDDIHY, R.; CUSHMAN, W.C.; GENUTH, S.; GRIMM, R.H.J.R.; HAMILTON, B.P.; HOOGWERF, B.; KARL, D.; KATZ, L.; KRICKORIAN, A.; O'CONNOR, P.; POP-BUSUI, R.; SCHUBART, U.; SIMMONS, D.; TAYLOR, H.; THOMAS, A.; WEISS, D.; HRAMIAC, I.; ACCORD TRIAL GROUP. Effect of intensive treatment of hyperglycaemia on microvascular outcomes in type 2 diabetes: an analysis of the ACCORD randomised trial. *Lancet*, v.376, p.419-430, 2010.
- KANG, T.H.; MOON, E.; HOMG, B.N.; CHOI, S.Z.; SON, M.; PARK, J.H.; KIM, S.Y. Diosgenin from *Dioscorea nipponica* ameliorates diabetic neuropathy by inducing nerve growth factor. *Biol. Pharm. Bull.*, v.34, p.1493-1498, 2011.
- KATSUBE, T.; YAMASAKI, M.; SHIWAKU, K.; ISHIJIMA, T.; MATSUMOTO, I.; ABE, K.; YAMASAKI, Y. Effect of flavonol glycoside in mulberry (*Morus alba* L.) leaf on glucose metabolism and oxidative stress in liver in diet-induced obese mice. *J. Sci. Food Agric.*, v.90, p.2386-2392, 2010.
- KIM, H.J.; YOON, K.H.; KANG, M.J.; YIM, H.W.; LEE, K.S.; VUKSAN, V.; SUNG, M.K. A six-month supplementation of mulberry, korean red ginseng, and banaba decreases biomarkers of systemic low-grade inflammation in subjects with impaired glucose tolerance and type 2 diabetes. *Evid. Based Complement. Alternat. Med.*, v.2012, p.735191, 2012.
- LAPPE-SIEFKE, C.; GOEBBELS, S.; GRAVEL, M.; NICKSCH, E.; LEE, J.; BRAUN, P.E.; GRIFFITHS, I.R.; NAVE, K.A. Disruption of *Cnp1* uncouples oligodendroglial functions in axonal support and myelination. *Nat. Genet.*, v.33, p.366-374, 2003.
- NAOWABOOT, J.; PANNANGPETCH, P.; KUKONGVIRIYAPAN, V.; KONGYINGYONES, B.; KUKONGVIRIYAPAN, U. Antihyperglycemic, antioxidant and antiglycation activities of mulberry leaf extract in streptozotocin-induced chronic diabetic rats. *Plant Foods Hum. Nutr.*, v.64, p.116-121, 2009a.
- NAOWABOOT, J.; PANNANGPETCH, P.; KUKONGVIRIYAPAN, V.; KUKONGVIRIYAPAN, U.; NAKMAREONG, S.; ITHARAT, A. Mulberry leaf extract restores arterial pressure in streptozotocin-induced chronic diabetic rats. *Nutr. Res.*, v.29, p.602-608, 2009b.
- OMRAN, O.M. Histopathological study of evening primrose oil effects on experimental diabetic neuropathy. *Ultrastruct. Pathol.*, v.36, p.222-227, 2012.
- SINGAB, A.N.; EL-BESHBISHY, H.A.; YONEKAWA, M.; NOMURA, T.; FUKAI, T. Hypoglycemic effect of Egyptian *Morus alba* root bark extract: Effect in diabetes and lipid peroxidation of streptozotocin-induced diabetic rats. *J. Ethnopharmacol.*, v.100, p.333-338, 2005.
- THOMAS, P.K. Diabetic neuropathy: mechanisms and future treatment options. *J. Neurol. Neurosurg. Psychiatry*, v.67, p.277-279, 1999.
- VEIGA, S.; LEONELLI, E.; BEELKE, M.; GARCIA-SEGURA, L.M.; MELCANGI, R.C. Neuroactive steroids prevent peripheral myelin alterations induced by diabetes. *Neurosci. Lett.*, v.402, p.150-153, 2006.
- VERMA, L.; SINGOUR, P.K.; CHAURASIYA, P.K.; RAJAK, H.; PAWAR, R.S.; PATIL, U.K. Effect of ethanolic extract of *Cassia occidentalis* Linn. for the management of alloxan-induced diabetic rats. *Pharmacognosy Res.*, v.2, p.132-137, 2010.

Received for publication on 12th May 2013
Accepted for publication on 09 August 2013

