

Late treatment of a mandibular gunshot wound

Yuri Slusarenko da Silva^a, Marcia Maria de Gouveia^a,
Carlos Augusto Ferreira Alves^a, Rodrigo Chenu Migliolo^a

Silva YS, Gouveia MM, Alves CAF, Migliolo RC. Late treatment of a mandibular gunshot wound. *Autopsy Case Rep* [Internet]. 2015; 5(1):53-59. <http://dx.doi.org/10.4322/acr.2014.051>

ABSTRACT

Mandibular gunshot injuries are esthetically and functionally devastating, causing comminuted fractures and adjacent tissue destruction depending on the weapon gauge, projectile shape, impact kinetic energy, and density of the injured structures. If the mandibular fracture is not adequate or promptly treated, the broken fragments will fail to heal. In case of a treatment delay, progressive bone loss and fracture contracture will require a customized approach, which includes open reduction, removal of fibrous tissue between the bony stumps, and fixation of the fracture with a reconstruction plate and autogenous graft. The authors report the case of a 34-year-old man wounded on the mandible 15 years ago. With the aid of computed tomography and a prototype, a surgical plan was designed including open reduction and internal fixation of the segmental mandibular defect with a reconstruction plate and bone graft harvested from the iliac crest. The postoperative follow-up was uneventful and the 12-month follow up showed a positive aesthetic and functional result.

Keywords

Wounds, Gunshot; Mandibular Fractures; Jaw Fixation Techniques; Mandibular Reconstruction.

INTRODUCTION

Several studies demonstrate the high incidence of gunshot injuries to the head and neck among civilians,¹⁻³ which are frequently fatal,³ mainly due to airway involvement and hemodynamic instability⁴ in accordance with the classic trimodal distribution of trauma deaths.

These injuries are either accidentally caused or due to suicide attempts, homicides, or robberies.^{1,3} The severity of these injuries varies according to the weapon gauge and its distance to the target,^{2,4} causing penetration, perforation, or avulsion of the involved tissue.³ Shotguns fired next to the victim (3 meters distance) are generally devastating or cause death.^{2,3}

Surgeons should be trained to recognize the type of injuries caused by different weapons, and therefore diagnose the extent of the injury,² since, in these cases, obtaining the patient's or witnesses' information is somewhat challenging.⁴

Theoretically, the establishment of the wound extent depends on the kinetic energy of the projectile and its interaction with the specific tissue.^{2,3} In this setting, the kinetic energy formula exponent ($KE = 1/2 MV^2$, where $M = \text{mass}$ and $V = \text{velocity}$) differs from soft to hard tissues, which is 0.5 and 2.5, respectively. In other words, when a hard structure is struck, the final formula will be: $KE = 1/2 MV^{2.5}$

^a Oral and Maxillofacial Surgery Department - University Hospital - University of Sao Paulo, São Paulo/SP, Brazil.



Therefore, as the mandible is structurally more cortical than cancellous, when it is hit by a projectile, bone will be fragmented³ and soft tissue damaged.

According to the speed, projectile shape, and injured anatomic region of the head and neck, these wounds will be more or less destructive, depending on the dissipated energy. In cases of high-energy dissipation, the impact will create a temporary tissue cavity reaching 11 times the projectile size, and this “shock wave” will damage distant vessels and nerves.^{2,3,5}

The initial therapeutic approach to all patients is based on the Advance Trauma Life Support (ATLS) to exclude life-threatening lesions.¹⁻⁴ After respiratory and hemodynamic stabilization, the recommended treatment for the mandibular gunshot injury comprehends the immediate⁴ copious saline irrigation, necrotic tissue and debris removal,³ open reduction, fracture stabilization, and rigid internal fixation with a mandibular reconstruction plate.^{6,7} The choice between the primary or secondary bone graft reconstruction⁴ should be evaluated depending on the local receptor area conditions, especially regarding the infection risk.³ Autogenous non-vascularized bone grafts, harvested from the anterior or the posterior iliac crest,⁸ are frequently used, unless the case severity requires a vascularized fibular graft. In the event that these injuries are not promptly nor adequately treated, the fracture will not heal and progressive bone loss as well as soft tissue contracture will ensue.^{4,9}

The late treatment requires a customized approach, including the open reduction; fibrous tissue removal, and fragments stabilization with a heavy plate reconstruction of the mandibular perimeter.^{8,9} In order to optimize the results regarding a satisfactory mandibular rehabilitation, the preoperative planning should be based on a prototype¹⁰, which will allow a better choice of the fixation device and graft, as well as to prebend the plate, which will decrease the intraoperative time.^{6,8}

We report the case of a patient with sequelae from a non-treated mandibular gunshot injury.

CASE REPORT

A 32-year-old man arrived at the Oral and Maxillofacial Surgery Department with a history of having been shot 15 years ago. During those years,

the patient could not be treated because of the lack of financial support and social conditions. External examination revealed a depression in the projection of the left mandibular body, shortening of the mandibular length (Figure 1A and B) and mobility of the mandibular body, which was adequately covered by soft tissue (Figure 2).

No spontaneous occlusion was observed due to the lack of some superior and inferior teeth. A craniofacial computed tomography (CT) was performed and prototypes of mandible and face were manipulated, which demonstrated a segmental defect of the left mandibular body. The prototype was manipulated and adjusted following some craniometric points, aligning together the midline of the face and the mandible. The condyles were set in their best fossae position. A 5 cm defect could be determined, which was filled with auto-cure resin to maintain the structural positions (Figure 3).

A long and heavy mandibular plate extending from the mandibular ramus to the symphysis was prebent preoperatively and an occlusal guide was fabricated to stabilize the mandible position to the maxilla (Figure 4).

The surgery was undertaken under general anesthesia with nasal intubation, permitting free manipulation of the patient to set an ideal occlusal relationship before fastening the plate, which was step aided by the occlusal guide. A submandibular approach with anterior extension was sufficient to show the segmental defect. The fragments were repositioned, stabilized, and fixed with the prebent mandibular reconstruction plate that was perfectly adapted without any complementary adjustments. An autogenous corticocancellous free and non-vascularized graft measuring 9 cm was harvested from the left iliac crest, which was adapted to increase the contact surface with the lingual aspect of the proximal stump, improving the graft's stability and blood supply. The graft was fixed in an interfragmentary manner with two long screws of 2.4 system and the plate was further fixed to the mandible. Additional graft stability was gained with a four holes 2.0 system plate fixed to the graft (Figure 5).

The postoperative period was uneventful, local or systemic infection was not detected during the 6-month follow up and bone graft maintained viability. The control CT demonstrated adequate bone

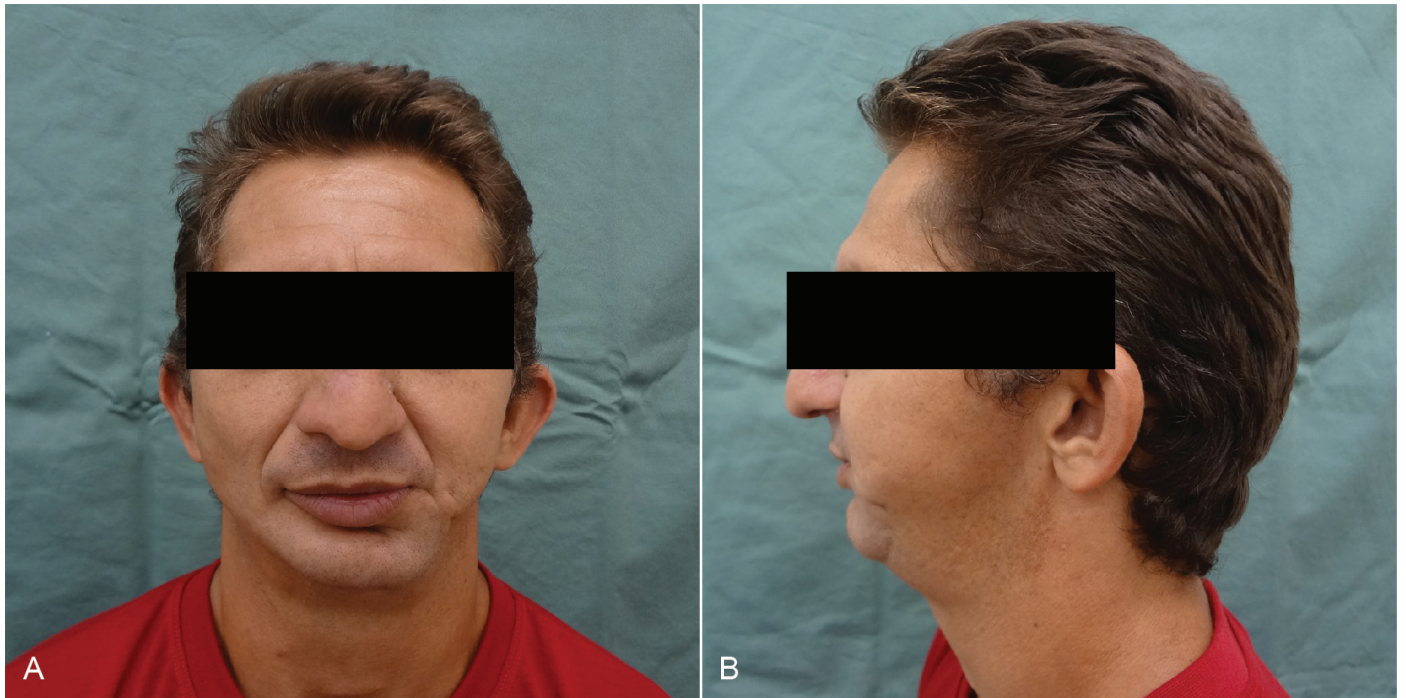

Figure 1. **A** - note the depression in the left mandible body; in **B** - note the shortening of the anteroposterior mandibular length.

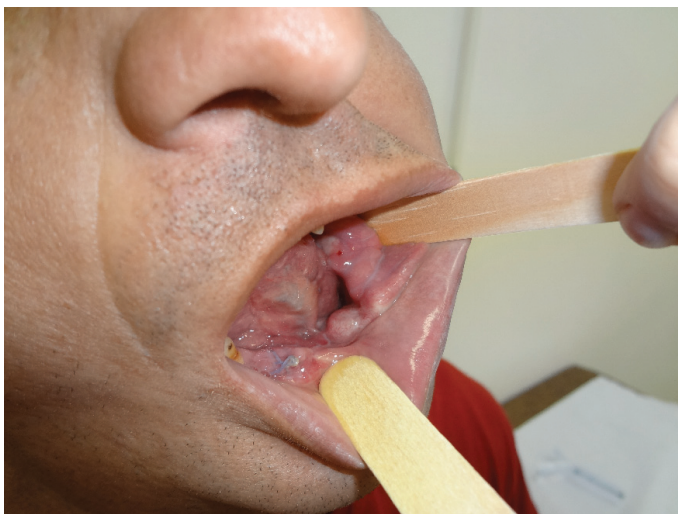

Figure 2. Intraoral aspect. It is possible to note the segmental defect between the wood spatulas.

tissue for the further insertion of implants. At the sixth month, the patient was referred for oral rehabilitation. Physiotherapy began with the objective of improving his maximal open mouth until 40 mm was reached and muscular function was re-established (Figure 6). Figure 7 shows the long-term postoperative aesthetics vision and the amplitude of mouth opening.

DISCUSSION

The treatment of mandibular gunshot injuries is challenging from the initial ATLS approach to the bone reconstruction techniques.¹

It is necessary to differentiate delayed treatment from late treatment. The former consists of closed treatment with maxillomandibular fixation, or the use of an external pin to stabilize the fragments for 3–6 months,³ while the latter refers to the patient with no prompt care developing mal-union or non-union of bone segments and consequently malocclusion.^{1,6,8}

The conservative treatment of mandibular gunshot wounds was formerly recommended² based on the bone fragments' viability assured by the periosteal contact. Another concern was the presence of wound infection. However, recent studies recommend primary reconstruction^{1,3,4} accompanied by immediate open reduction of fractures and internal rigid fixation using a titanium reconstruction plate of at least 3 mm thickness and 5 mm width^{6,7} placed at the inferior border.⁷ In case a vascularized graft is required, it is cautious to wait until vascular derangements are solved, like thrombosis, swelling, and venous congestion.³ Nevertheless, a temporary reconstruction plate may

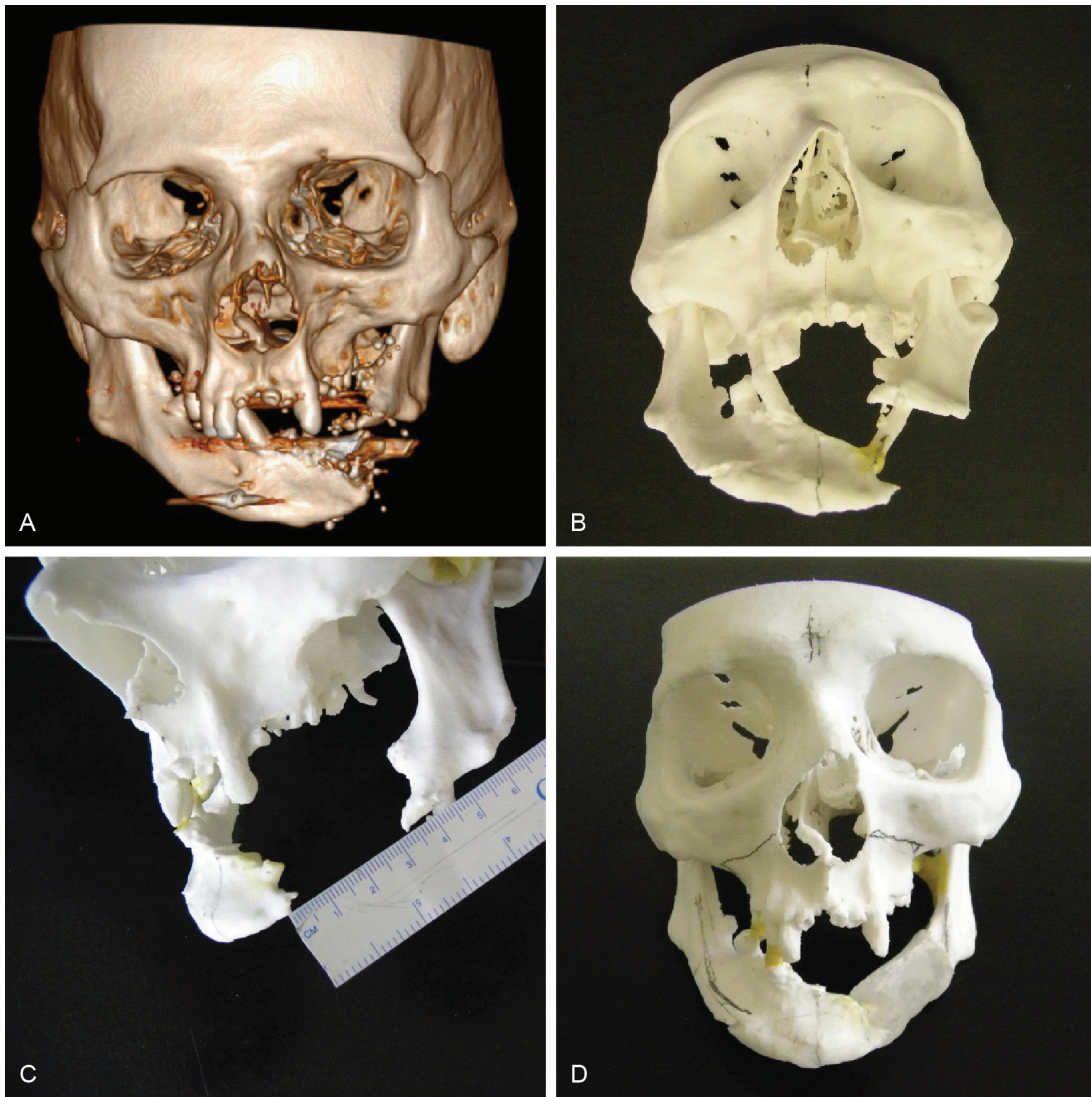


Figure 3. **A** - Frontal view of 3D CT reconstruction demonstrating the initial aspect of the mandibular fracture; **B** - Frontal view of the prototype, mimicking the CT image shown in **A**; **C** - The segmental defect measured 5 cm; **D** - The acrylic was placed in the defect to re-establish the original anatomy of the mandible.

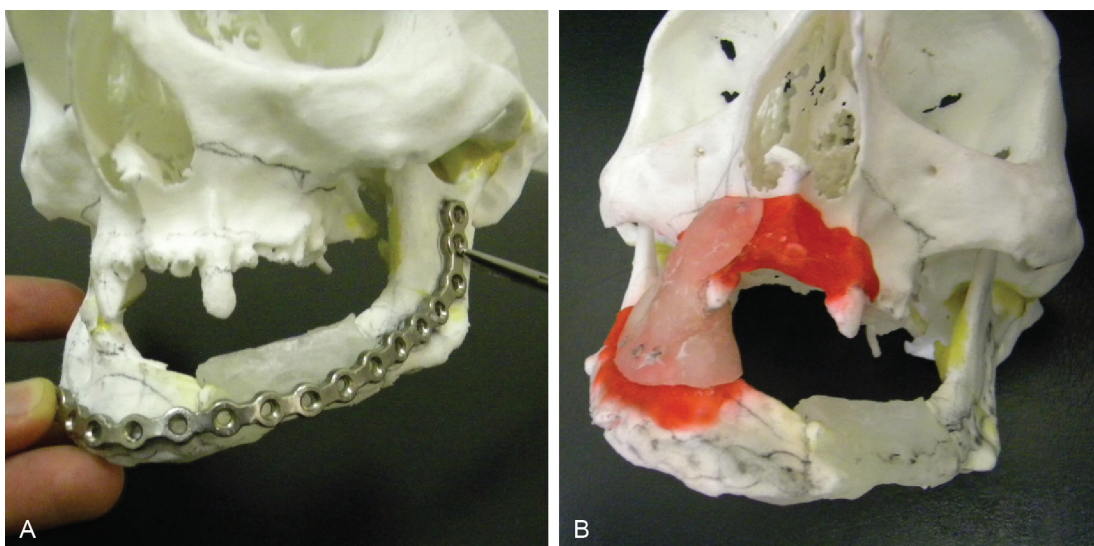


Figure 4. **A** - A long prebent plate molded to the prototype, from mandibular ramus to symphysis; **B** - The occlusal guide in position.

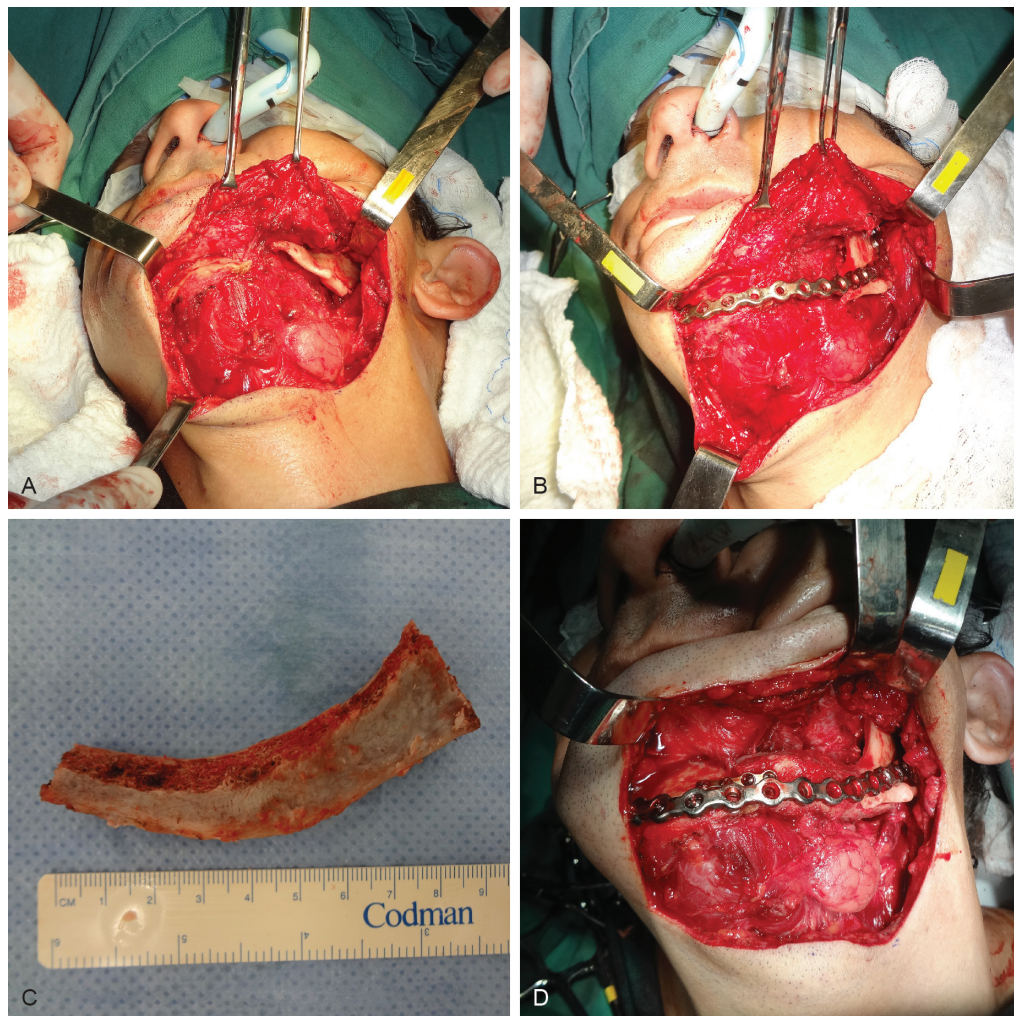


Figure 5. **A** - An extended submandibular approach was enough to see all defects and adapt the whole plate and graft without excessive tissues traction; **B** - The plate with at least 4 screws was fixed to each side of the defect; **C** - corticocancellous bone graft from the left iliac crest, which size and shape were adequate to reproduce an ideal alveolar ridge; **D** - The graft was fixed to the plate, spanning the defect.

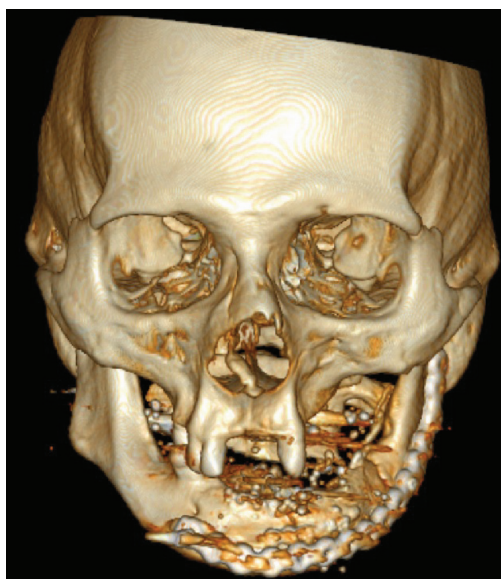

Figure 6. Five months CT – 3D reconstruction control; final aspect.

be fixed as a manner to stabilize the fragments and the three-dimensional mandibular format,⁷ thus preventing excessive soft-tissue retraction.

The present report demonstrates the feasibility to treat a patient 15 years after the trauma. The concepts aforementioned helped us to design an elective therapeutic plan aiming the re-establishment of stomatognathic system.^{8,9} Even in the presence of excessive tissue retractions and muscular atrophy, the viability of the non-vascularized graft was assured by the sufficient remaining soft tissue.⁷ After a prototype manipulation, a segmental mandibular defect of 5 cm was detected, leading us to use an autogenous corticocancellous bone graft.⁸ This technique, besides reproducing the mandibular alveolar ridge,^{3,7} optimizes the osseointegration process through the presence

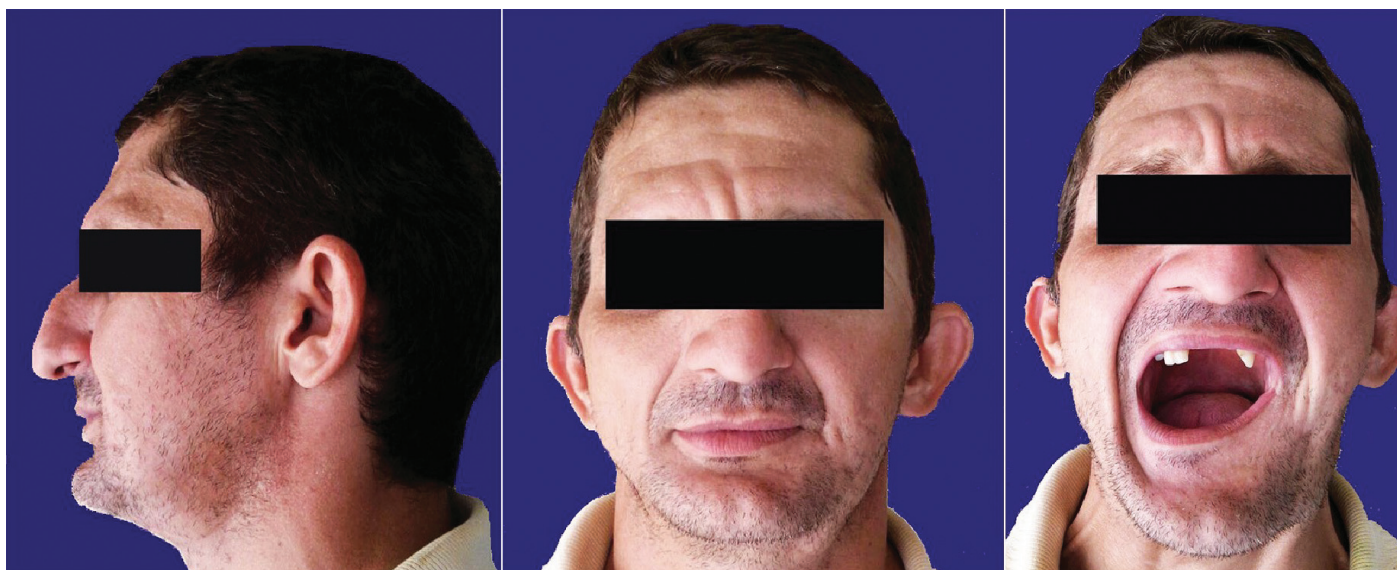

Figure 7. Aesthetic view and mouth opening amplitude after 12 months of the surgery.

of osteocompetent cells.^{3,8} The use of a prototype reduced the operation time significantly, since all plate adjustments could be undertaken before the surgery.¹⁰ The postoperative outcome was uneventful and the graft maintained viability and capacity to receive further osseointegrated dental implants.

FINAL CONSIDERATIONS

Despite scientific and medical advances, mandibular reconstruction after a gunshot wound remains challenging. Particularities of each case prevent a standardized therapeutic approach. CT imaging and the use of preoperative prototyping will help the clinician to choose the best graft characteristics as well as pre bending the plate. Defects up to 5 cm in length with sufficient intraoral and extra oral soft tissue covering are prone to receive a free and non-vascularized bone graft.

ACKNOWLEDGMENTS

The authors are thankful for the Center for Information Technology Renato Archer, Campinas/SP, Brazil, for the prototyping confection.

REFERENCES

1. Rana M, Warraich R, Rashad A, et al. Management of comminuted but continuous mandible defects after gunshot injuries. *Injury*. 2014;45(1):206-11. <http://dx.doi.org/10.1016/j.injury.2012.09.021>. PMID:23084488
2. Walker RV, Frame JW. Civilian maxillo-facial gunshot injuries. *Int J Oral Surg*. 1984;13(4):263-77. [http://dx.doi.org/10.1016/S0300-9785\(84\)80033-2](http://dx.doi.org/10.1016/S0300-9785(84)80033-2). PMID:6434445
3. Cunningham LL, Haug RH, Ford J. Firearm injuries to the maxillofacial region: an overview of current thoughts regarding demographics, pathophysiology, and management. *J Oral Maxillofac Surg*. 2003;61(8):932-42. [http://dx.doi.org/10.1016/S0278-2391\(03\)00293-3](http://dx.doi.org/10.1016/S0278-2391(03)00293-3). PMID:12905447
4. Hollier L, Grantcharova EP, Kattash M. Facial gunshot wounds: a 4-year experience. *J Oral Maxillofac Surg*. 2001;59(3):277-82. <http://dx.doi.org/10.1053/joms.2001.20989>. PMID:11243609
5. Powers DB, Delo RI. Characteristics of ballistic and blast injuries. *Atlas Oral Maxillofac Surg Clin North Am*. 2013;21(1):15-24. <http://dx.doi.org/10.1016/j.cxom.2012.12.001>. PMID:23498328
6. Bak M, Jacobson AS, Buchbinder D, Urken ML. Contemporary reconstruction of the mandible. *Oral Oncol*. 2010;46(2):71-6. <http://dx.doi.org/10.1016/j.oraloncology.2009.11.006>. PMID:20036611
7. Goh BT, Lee S, Tideman H, Stoelinga PJ. Mandibular reconstruction in adults: a review. *Int J Oral Maxillofac Surg*. 2008;37(7):597-605. <http://dx.doi.org/10.1016/j.ijom.2008.03.002>. PMID:18450424

8. Kademani D, Keller E. Iliac crest grafting for mandibular reconstruction. *Atlas Oral Maxillofac Surg Clin North Am.* 2006;14(2):161-70. <http://dx.doi.org/10.1016/j.cxom.2006.05.005>. PMID:16959603
9. Coletti DP, Caccamese JF. Diagnosis and management of mandible fractures. In: Fonseca RJ, editor. *Oral and maxillofacial surgery*. Philadelphia: W.B. Saunders Company; 2004. chapter 10; p. 139-61.
10. Primo BT, Presotto AC, de Oliveira HW, et al. Accuracy assessment of prototypes produced using multi-slice and cone-beam computed tomography. *Int J Oral Maxillofac Surg.* 2012;41(10):1291-5. <http://dx.doi.org/10.1016/j.ijom.2012.04.013>. PMID:22578568

Conflict of interest: None

Submitted on: January 1, 2014

Accepted on: February 2, 2015

Correspondence

Yuri Slusarenko da Silva

Divisão de Odontologia Hospital Universitário da Universidade de São Paulo

Av. Prof. Lineu Prestes, 2565 – Cidade Universitária – São Paulo/SP – Brazil

CEP: 05508-000

Phone: +55 (11) 3091-9200

E-mail: yu.slu@hotmail.com