

Budd–Chiari Syndrome: an unnoticed diagnosis

Camila Kruschewsky Falcão^a, Gustavo C. Freitas Fagundes^a, Gustavo Checulli Lamos^a,
Aloisio Felipe-Silva^b, Silvana Maria Lovisollo^b, João Augusto Martines^c,
Fernando Peixoto Ferraz de Campos^d

Falcão CK, Fagundes GCF, Lamos GC, et al. Budd–Chiari Syndrome: an unnoticed diagnosis. *Autopsy Case Rep* [Internet]. 2015; 5(2):17-25. <http://dx.doi.org/10.4322/acr.2015.009>

ABSTRACT

Budd–Chiari syndrome (BCS) encompasses a group of disorders caused by the obstruction to the hepatic venous outflow at the level of the small or large hepatic veins, the inferior vena cava, or any combination thereof. Clinical manifestation of the subacute form is characterized by supramesocolic abdominal discomfort, abdominal distension, fever, and lower limbs edema. Imaging work-up with hepatic Doppler ultrasound and abdominal computed tomography (CT) enables the diagnosis in the majority of cases. Treatment comprises long-term anticoagulation associated with measures that attempt to re-establish the flow in the thrombosed vessel (thrombolysis or angioplasty) or through the venous blood flow bypasses (transjugular intrahepatic portosystemic shunt or surgical bypass); however, the outcome is often dismal. The authors report the case of a 37-year-old woman presenting a 2-month history of dyspeptic complaints and abdominal distention. Fever was present at the beginning of symptoms. The laboratory work-up disclosed mild hepatic dysfunction, and the ultrasound showed evidence of chronic liver disease. Despite a thorough etiologic investigation, diagnosis was missed and, therefore, management could not be directed towards the physiopathogenetic process. The outcome was characterized by portal hypertension and esophageal varices bleeding. The patient died and the autopsy findings were characteristic of BCS, although an abdominal CT, close to death, had showed signs consistent with this diagnosis. The authors highlight the importance of knowledge of this entity, the diagnostic methods, and the multidisciplinary approach. BCS should be considered whenever investigating etiology for chronic or acute hepatopathy.

Keywords

Budd–Chiari Syndrome; Hypertension, Portal; Liver Cirrhosis; Ascites; Autopsy.

CASE REPORT

A 37-year-old, previously healthy, Caucasian female patient sought medical care, complaining of a 2-month history of abdominal discomfort, nausea, vomiting, lack of appetite, weight loss (6 kg in

2 months), and fever at the beginning of the symptoms. She denied alcohol consumption, tobacco smoking, use of medications or illicit drugs, contraceptives, previous hemotransfusion, or surgical procedure.

^a Internal Medicine Department - Hospital das Clínicas - Faculdade de Medicina - Universidade de São Paulo, São Paulo/SP - Brazil.

^b Anatomy Pathology Service - Hospital Universitário - Universidade de São Paulo, São Paulo/SP - Brazil.

^c Radiology Department - Hospital Universitário - Universidade de São Paulo, São Paulo/SP - Brazil.

^d Internal Medicine Department - Hospital Universitário - Universidade de São Paulo, São Paulo/SP - Brazil.



The physical examination showed a well-looking patient with normal hemodynamic parameters, who weighed 69 kg, and had a body mass index of 29. The abdomen was mildly distended, the liver was palpable until 4 cm below the right costal margin, and Traube's space was dull on percussion. The remaining physical examination was normal. The initial laboratory work-up is shown in Table 1.

The abdominal ultrasound examination showed an enlarged liver with diffuse heterogeneous and coarsened echotexture. Portal and hepatic veins as well as the gall bladder, the biliary tree, and the spleen were normal. A small amount of free fluid was present within the abdominal cavity. The abdominal computed tomography (CT) showed an enlarged liver and caudate lobe hypertrophy causing a narrowing of the inferior vena cava. Liver parenchyma showed heterogeneous attenuation coefficient with some nodules sketches. A small amount of free fluid was present in the abdominal cavity.

The patient did not attend the scheduled follow-up and 4 months later she entered the emergency room presenting hematemesis. The physical examination revealed normal hemodynamic parameters and neurological status; however, moderate ascites and right pleural effusion were detected. The upper digestive endoscopy disclosed esophageal varices and

hypertensive gastropathy; the former were tied off with elastic bands. On this occasion the hepatic Doppler ultrasound showed the venous portal system without signs of thrombosis with monophasic waveform and normal peak systolic velocity. The left and middle hepatic veins were pervious with normal flow direction, but the right hepatic vein, as well as the gastric and splenic veins, could not be accessed.

Continuing the investigation of the hepatopathy, the iron profile tests, ceruloplasmin, and alpha-1 antitrypsin were normal. The protein electrophoresis showed a polyclonal hypergamaglobulinemia. The antinuclear antibody test was negative, and the search for anti-liver cytosol, antiparietal cell, anti-mitochondrial, anti-LKM-1, and anti-smooth muscle antibodies was also negative.

The patient was submitted to a liver biopsy, the histological findings of which were at first interpreted as moderate active liver cirrhosis without cholestasis, iron deposition, or steatosis. She was referred to a liver transplantation service, but was considered not eligible because her MELD (model for end-stage liver disease) score was 12, which is under the limit for liver transplantation in Brazil in 2015. A diagnosis of cryptogenic cirrhosis was rendered.

The clinical outcome was troublesome, and the patient developed a refractory ascites, requiring

Table 1. Initial laboratory investigation

Exam	Result	RV	Exam	Result	RV
Hemoglobin	13.1	12.3–15.3 g/dL	ALT	31	9–36 U/L
Hematocrit	40.5	36.0–45.0%	AST	46	10–31 U/L
Leukocytes	6.44	4.4–11.3 × 10 ³ /mm ³	AP	120	10–100 U/L
Segmented	59	45–70%	γGT	177	2–30 U/L
Eosinophils	2	1–4%	LDH	272	120–246 U/L
Lymphocytes	30	18–40%	TP	7.8	6.0–8.0 g/dL
Monocytes	9	2–9%	Albumin	4.1	3.0–5.0 g/dL
Platelets	141	150–400 × 10 ³ /mm ³	TB	1.28	0.3–1.2 mg/dL
INR	1.45	1	Amylase	87	30–118 U/L
Urea	19	5–25 mg/dL	Lipase	43	13–60 U/L
Creatinine	0.4	0.4–1.3 mg/dL	CRP	9	< 5 mg/L
Potassium	4.3	3.5–5.0 mEq/L	anti-HIV	Negative	
Sodium	139	136–146 mEq/L	anti-HCV	Negative	
Glucose	93	< 99 mg/dL	anti-HBV (serology)	Negative	

ALT = alanine aminotransferase. AP = alkaline phosphatase. AST = aspartate aminotransferase. CRP = C-reactive protein. γGT = gamma-glutamyl transpeptidase. LDH = lactate dehydrogenase. RV = reference value. TB = total bilirubin. TP = total protein.

repeated paracentesis. After 9 months since the beginning of symptoms, she had lost 12 kg (6 kg of which were lost in the last 2 months) and presented weakness, vomiting, abdominal pain, and dyspnea. She was hospitalized with severe hyponatremia. At this time, another abdominal CT was performed, which revealed heterogeneity of the attenuation coefficient of the liver parenchyma, narrowing of the intra hepatic portion of the inferior vena cava, thrombosis of the portal vein, and non-contrasting hepatic veins besides a possible thrombosis of the anomalous hepatic vein that was not filled in by contrast (Figure 1). The examination of the peritoneal fluid ruled out the diagnosis of spontaneous bacterial peritonitis, but, unfortunately, acute renal failure ensued and the patient died after 5 days due to septic shock of an unidentified site.

AUTOPSY FINDINGS

The autopsy revealed an emaciated female corpse with moderate ascites and bilateral pleural effusions.

The liver was enlarged, micronodular, and intensely reddened. Collapsing areas of parenchymal loss were seen (Figure 2A). Hepatic veins could not be individualized due to organizing macroscopic

thrombosis, which could be seen on the liver cut surface (Figure 2B). Thrombosis was not identified in the inferior vena cava or the portal vein. On microscopic examination, the liver was cirrhotic (Figure 2C), with mild-to-moderate inflammatory infiltrate with lymphocytes, histiocytes, and some neutrophils (Figure 2D).

The central and portal veins showed multiple organizing thrombosis (Figure 3A–C), sometimes with near total obliteration of the portal branches (Figure 3D). Areas of recent and organizing hepatocyte necrosis were seen throughout the liver. The gallbladder and the biliary tract were normal, except for a moderate ductular reaction related to cirrhosis.

The spleen was enlarged and congested while uncomplicated esophageal varices could be noted on the distal half of the esophagus. The bowels were grossly purplish and friable. Histological examination confirmed transmural small bowel infarction with local thrombosis and bacterial proliferation (Figure 4A and B).

While the heart and pericardium were normal, the lungs were friable, reddish, boggy, and heavy. Upon microscopic examination, the lungs showed intense congestion, edema, septic emboli and multifocal bronchopneumonia (Figure 4C and D).

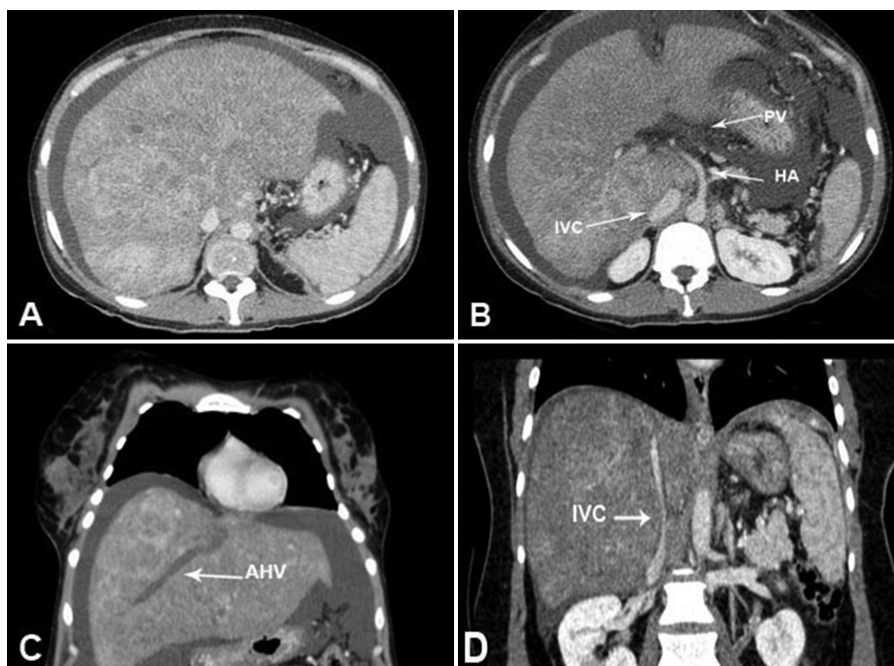


Figure 1. Abdominal computed tomography—portal phase. **A** – Attenuation coefficient heterogeneity of the hepatic parenchyma. **B** – Portal vein (PV) thrombosis compression of the inferior vena cava (IVC) by the caudate lobe. **C** – Unfilled anomalous hepatic vein. **D** – Narrowing of the inferior vena cava. AHV = anomalous hepatic vein. HA = hepatic artery.

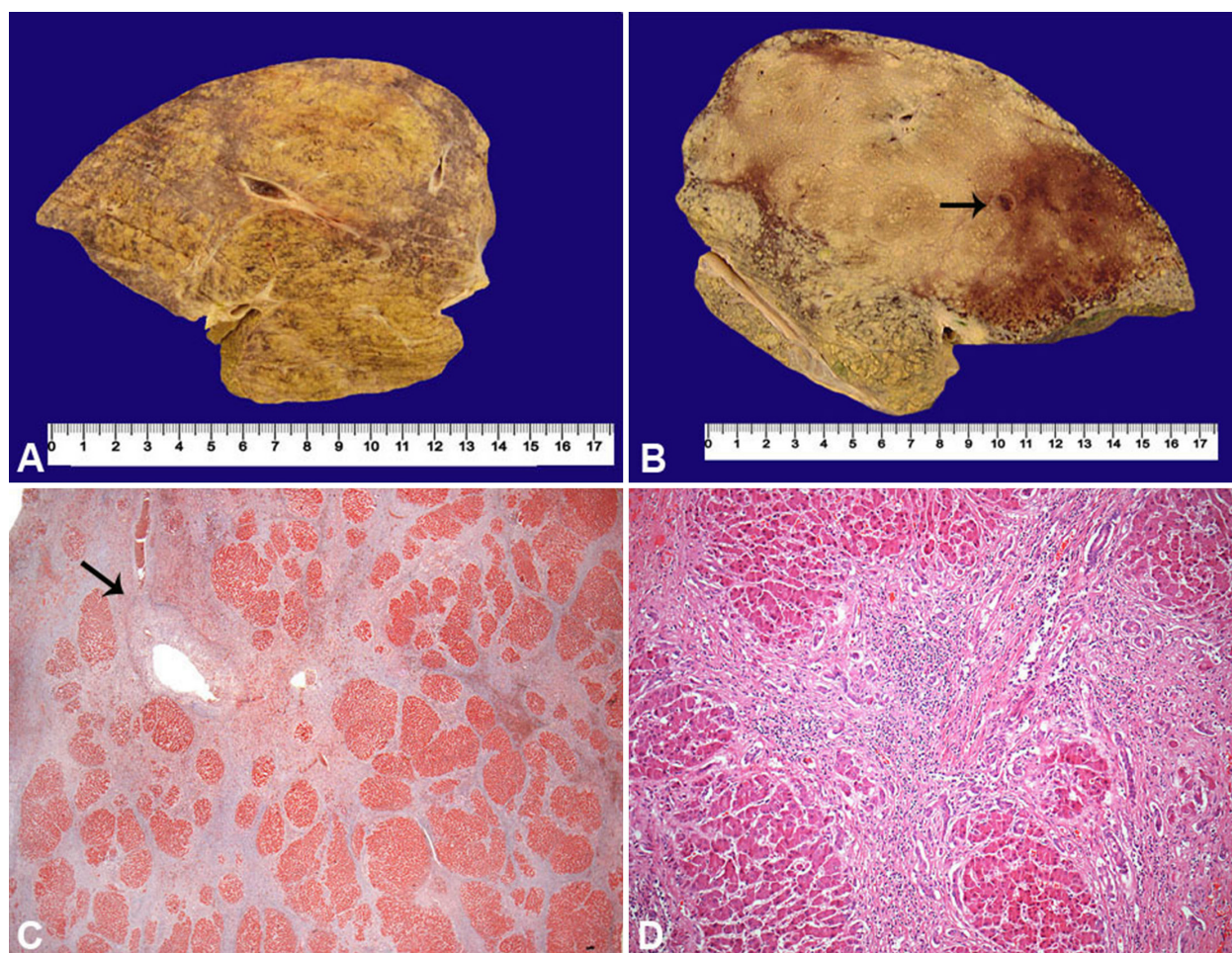


Figure 2. **A** and **B** – Gross examination of the cut surface of the liver (formalin fixed) showing micronodular aspect with collapsing areas (dark purple areas). The arrow in **B** shows an organizing thrombus in the segmental hepatic vein. **C** – Photomicrography of the liver showing nodular transformation (cirrhosis) and an organizing thrombus in a central vein (arrow) (Masson trichrome, 12.5X). **D** – Photomicrography of the liver showing moderate inflammation in fibrous septa mimicking an ordinary inflammatory cirrhosis (H&E, 100X).

Other signs of sepsis and shock were detected in the pancreas (focal ischemic pancreatitis), kidneys (acute tubular necrosis), and adrenals (ischemic changes). Focal capillary thrombosis was found in the lungs, which was consistent with disseminated intravascular coagulation, and reactive erythrophagocytosis in the lymph nodes. The bone marrow showed reactive hypercellularity but no signs of dysplasia, malignancy, or hematological disorder were found.

In summary, the autopsy findings were consistent with veno-portal cirrhosis due to Budd–Chiari syndrome (BCS) with complicated portal hypertension, final bowel infarction, and septic shock.

In fact, revision of the liver biopsy slides confirmed the impression of cirrhosis with moderate inflammation. However, signs of complicated venous outflow blockage disease, such as sinusoidal dilatation and lobular necrosis, were present. Some

portal and central veins showed luminal obliteration and fibrosis, which were unnoticed at the first analysis (Figure 5 A–D).

DISCUSSION

BCS is a rare hepatic disorder resulting from the complete or incomplete hepatic venous outflow obstruction that may take place either in the small and large hepatic veins and/or the inferior vena cava leading to liver damage and portal hypertension.^{1,2} Despite the scarcity of epidemiological data, the presentation seems to differ according to geographical differences. In Western countries, women in the third or fourth decade of life are most affected, and involvement of the hepatic veins predominates.^{3–5} In 1845, the English physician, George Budd, first published the triad of abdominal pain, hepatomegaly, and ascites associated

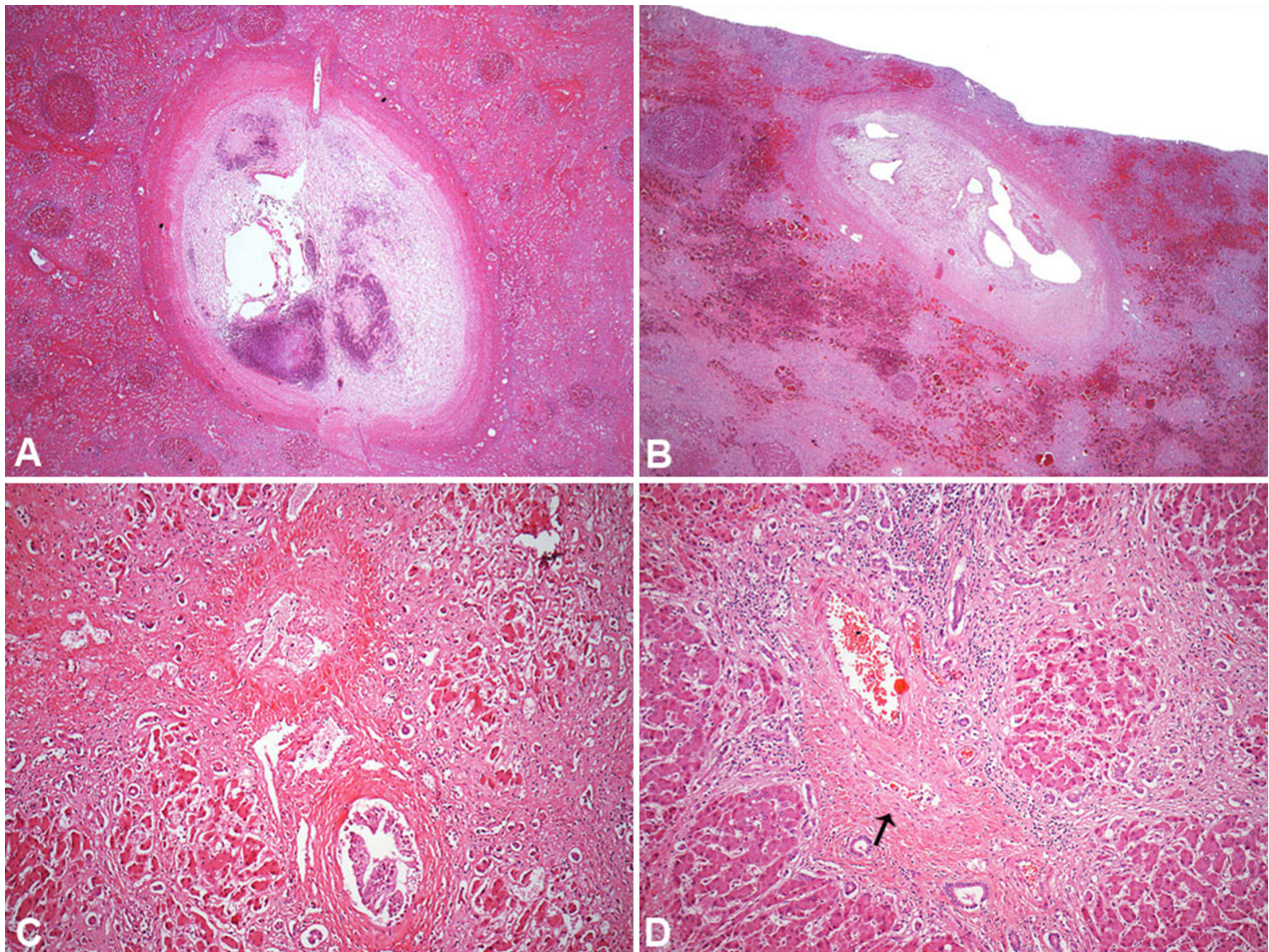


Figure 3. Photomicrography of the liver. **A** – Organizing thrombus in a segmental hepatic vein (same as in Figure 2B) (H&E, 100X). **B** – Recanalized thrombus in a segmental hepatic vein (H&E, 100X). **C** – Abnormal portal tract with extensive fibrosis and sclerosis of portal vein (H&E, 200X). **D** – Abnormal portal tract with fibrosis, inflammation and sclerosis of portal vein (arrow) (H&E, 200X).

with hepatic venous outflow obstruction, in his treatise “Diseases of the Liver.” In 1899, the Austrian pathologist Hans Chiari described the histopathological features and, since then, the syndrome has been coined Budd–Chiari syndrome, although the disorder had been observed already and mentioned by Karl F. von Rokitsansky (1808–1878).^{6,7}

BCS is divided into two types. The “secondary type” is when a lesion (a benign or malignant tumor, trauma, an abscess, or a cyst), which originates outside the veins, causes an obstruction to the hepatic blood outflow (compression or invasion).¹ The “primary type” is when the obstruction (thrombosis or phlebitis) occurs within the vessel. Primary BCS occurs because of prothrombotic factors, either hereditary or acquired, which are identified in up to 87% of cases. Multiple causes in the same patient have been increasingly recognized and are present in 25% of cases.^{3,8,9} Myeloproliferative diseases particularly are the most

common causes, present in nearly 50% of cases of primary BCS, and among them polycythemia vera accounts for 10–40% of cases, followed by thrombophilia due to factor V Leiden mutation, prothrombin-gene mutation, antiphospholipid antibody syndrome, inherited deficiencies of protein C, protein S, and antithrombin III.^{2,3,10} Lupus anticoagulant or anti-beta-2 glycoprotein 1 antibodies may be found in smaller proportion along with other possible risk factors, such as paroxysmal nocturnal hemoglobinuria, Behçet’s disease, hypereosinophilic syndrome, granulomatous venulitis, and ulcerative colitis.^{1,3}

The relative risk of the development of BCS caused by contraceptives is up to 2.4% (similar to the relative risk of other site’s thrombosis); contraceptives are identified in half of the women with the diagnosis of BCS.^{2,9} Pregnancy and the puerperium are also considered predisposing factors. However, the likelihood of the development of BCS is increasingly

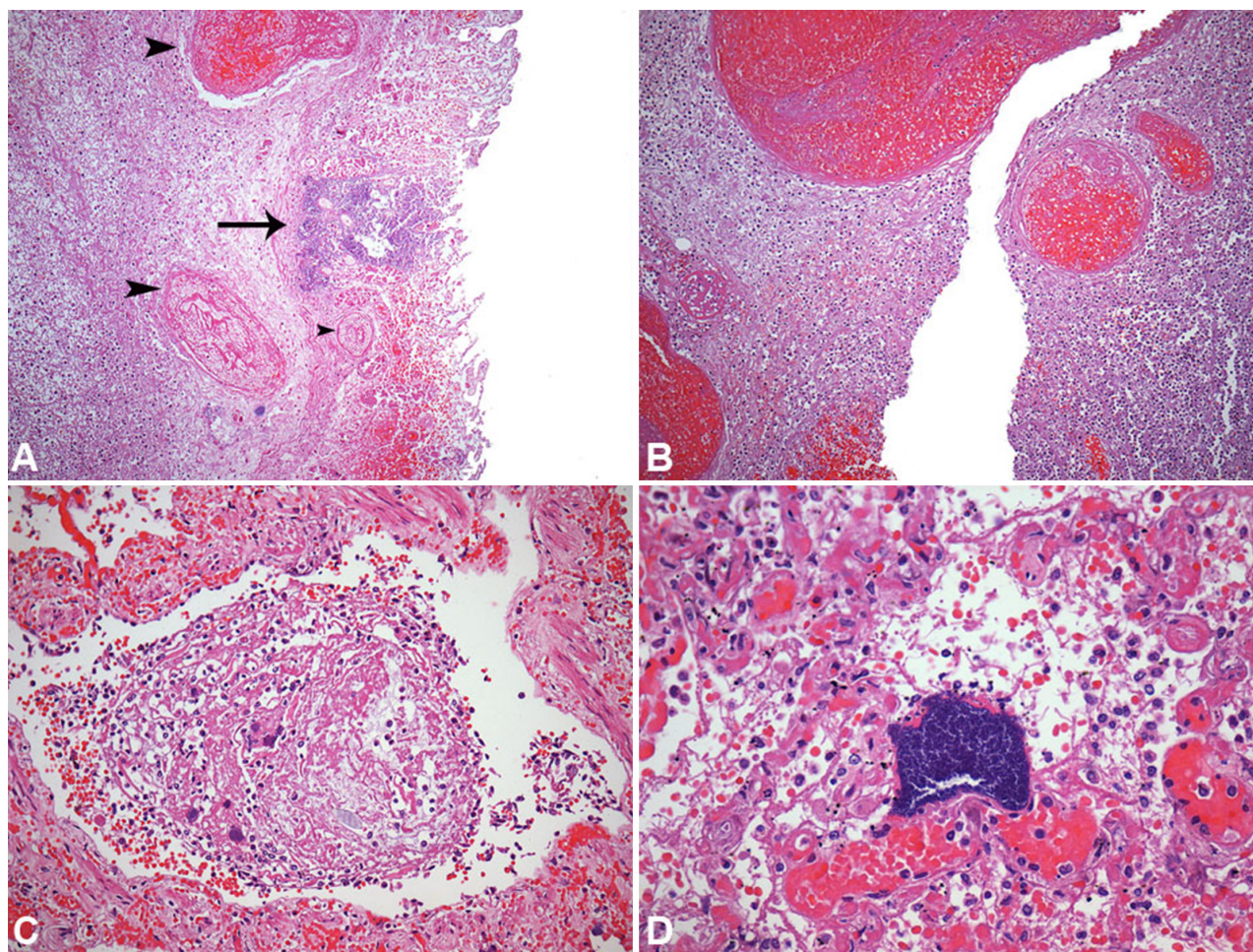


Figure 4. Photomicrography of other autopsy findings. **A** – Small bowel hemorrhagic infarct with bacterial colonies (arrow) and venous thrombi (arrowheads) (H&E, 200X). **B** – Small bowel mural infarction with extensive acute inflammation and thrombosis (H&E, 200X). **C** – Septic embolus in the lung with fibrin, neutrophils, and bacterial colonies (H&E, 200X). **D** – Hematogenous pneumonia with bacterial colony in alveolar capillaries (H&E, 400X).

recognized when these factors are associated with other underlying thrombophilia.^{2,9}

The extent and rapidity of hepatic vein occlusion, as well as the development of collateral circulation are responsible for the wide spectrum of clinical presentation, ranging from a fulminant form to a chronic disease, and indeed, from asymptomatic to full symptomatic cases. Fever, abdominal pain, abdominal distension, ascites, hepatomegaly, and lower limbs edema are the most common signs and symptoms.^{2,3,8,10} The subacute form, which is the most common presentation, is characterized by an insidious onset, generally within 3 months, clinical features of vague discomfort in the epigastrium or right hypochondrium, and mild ascites that increases with the disease progression (when portal hypertension ensues).^{8,9} Because the BCS is often missed in the differential diagnosis, patients with clinical and

laboratory findings consistent with hepatopathy are mistakenly diagnosed.²

The laboratory profile is non-specific. In the subacute form, mild elevation of hepatic enzymes, a decrease in serum albumin, a high serum-ascites albumin gradient, and a protein determination of usually more than 2.5 g/dL in the ascitic fluid. Hepatic failure, as well as higher determination of hepatic enzymes, may be present in the acute and fulminant forms.^{1,2}

Imaging examination is fundamental for the diagnosis.^{2,3} Once suspected, the diagnostic approach should start with the hepatic Doppler ultrasound that has an accuracy of up to 85%.¹¹ This technique allows the evaluation of the hepatic veins and the inferior vena cava blood flows that may be decreased, reversed, or absent in the BCS.^{5,11–13} Stenosis or dilation of these veins and the caudate lobe hypertrophy are

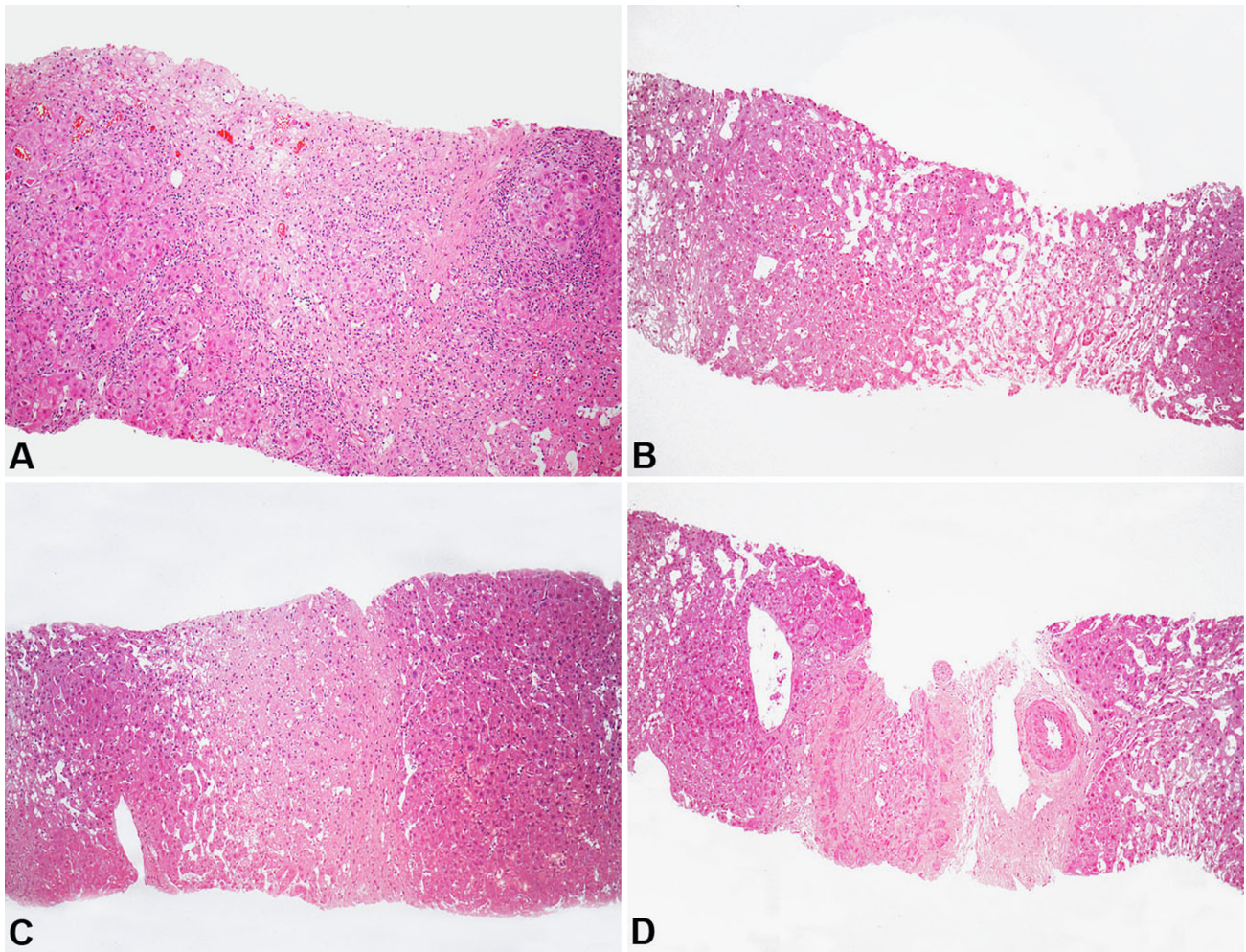


Figure 5. Photomicrography of the liver biopsy. **A** – Organizing collapsed areas with fibrosis and chronic inflammation. **B** – Sinusoidal dilatation. **C** – Recent focus of hepatic necrosis (collapse). **D** – Portal tract with organized portal vein thrombosis. (All images H&E, 100X).

other signs¹² (the latter, although non-specific, is present in 75% of cases).¹ In chronic cases, collateral veins are observed in the hepatic veins and/or inferior vena cava.^{1,2} Other imaging methods may be helpful in the diagnostic work-up, such as the CT that may show the presence of regenerative nodules, a delay of filling or an absence of the contrast medium in the hepatic veins and/or inferior vena cava, as well as unequal parenchymal contrast enhancement (called heterogeneous attenuation coefficient of the hepatic parenchyma) between the peripheral and central region of the liver.¹² However, 50% of the cases may show false-positive results, reinforcing the importance of the correlation with the Doppler ultrasound results.^{1,2,9}

In the case reported herein, the first abdominal CT did not clearly identify signs that could elucidate the etiology of the hepatopathy. The Doppler ultrasound, which was undertaken late in the course of this

patient's disease, showed normal blood flow through the left and middle hepatic veins as well as through the portal system. In this examination, the right hepatic vein was not accessed, which should have been highly considered as an obstruction of the blood flow, but as the gastric and splenic veins were not identified either, we dare considered that this fact may have interfered with the correct interpretation of the method. Magnetic resonance imaging is usually helpful in the differentiation of acute and chronic cases, and it helps to better evaluate the involvement of the inferior vena cava.¹³ The gold standard examination, for the diagnosis of BCS, is the hepatic venography that should be performed when the suspicion is high and any other imaging examination has failed to elucidate the problem.^{2,13,14}

Hepatic biopsy is rarely necessary and is indicated in doubtful cases.^{2,13} The histopathological features

comprise indirect findings of BCS, as congestion, sinusoidal dilation, hepatocytes loss, centrilobular fibrosis and bridging fibrosis. Intrahepatic portal vein thrombosis may be seen in advanced cases associated with large fibrosis of the portal tracts. Nodular regenerative hyperplasia and macroregenerative nodules are present in longstanding cases.^{1,15} These findings vary according to the duration and the intensity of obstruction.^{11,13} Diagnosis, quite often, requires an experienced pathologist. Unfortunately, the liver biopsy report of this patient did not mention any direct or indirect finding of BCS, but only cirrhosis. However, on the biopsy's revision, features consistent with BCS could be found.⁹ Unfortunately, the biopsy was performed late in the course of the disease, most probably because of the lack of follow-up, even though, at this advanced stage, some relief could have been offered to the patient, despite the gloomy prognosis.

Clinical suspicion of BCS is quite often challenging due to its rarity and the variety of clinical presentations.² Around 10–25% of BCS cases are idiopathic³ and in these cases, no risk factors are present, which can somehow influence clinical reasoning and a focused investigation. Incomplete or partial obstruction of the inferior vena cava and the hepatic vein branch may have an asymptomatic course and may be overlooked.¹⁶

Once the diagnosis is established, indefinite anticoagulation is prescribed for the cases associated with non-curable thrombophilia, as in other venous thrombosis territories.¹ Recently, transjugular intrahepatic portosystemic shunts have been increasingly used, mostly when vessel clearing by fibrinolysis, or angioplasty, or the anticoagulation did not succeed.¹⁷ Another therapeutic option for the decompression of the hepatic circulation remains in the portosystemic shunting at the expense of decreased portal venous inflow. However, this approach is related to high morbimortality. Liver transplantation may be considered in refractory cases to the standard or usual therapy, and for fulminant cases.

The treatment of BCS is far from an easy task and, like the diagnosis, often requires quite a multidisciplinary team. Preventing the progression to hepatic insufficiency should be the goal of the management of the patients with BCS, but complications related to the cirrhosis and/or portal hypertension also takes part of the management of BCS.^{1,12} Patients, submitted to hepatic

outflow clearing, present a favorable outcome and prognosis, showing a 5-year and 10-year survival rate of 80% and 75%, respectively.^{1,9,16}

The case reported herein illustrates a typical case of BCS with the Western presentation form that, unfortunately, was only diagnosed at autopsy. The final event, in this patient, was also due to thrombotic events. The necrosis of the small intestine and subsequent spread of infection, which was clearly demonstrated at autopsy, was the cause of death. We considered this misdiagnosis as a consequence of a series of inaccuracies, which relied on the interpretation of the diagnostic methods, and on clinical failure to gather all the medical staff involved in the patient's care. Although BCS is not among the most common causes of cirrhosis, this diagnosis should always be taken into account either in acute or chronic hepatopathy,^{2,18} and yet many diagnoses are still missed.

This case report demonstrates the importance in strongly pursuing the hepatic cirrhosis etiology, since, in some cases, it is possible to substantially change the outcome and prognosis.

REFERENCES

1. DeLeve LD, Valla DC, Garcia-Tsao G, American Association for the Study Liver Diseases. Vascular disorders of the liver. *Hepatology*. 2009;49(5):1729-64. <http://dx.doi.org/10.1002/hep.22772>. PMID:19399912.
2. Menon KV, Shah V, Kamath PS. The Budd-Chiari syndrome. *N Engl J Med*. 2004;350(6):578-85. <http://dx.doi.org/10.1056/NEJMra020282>. PMID:14762185.
3. Plessier A, Valla DC. Budd-Chiari syndrome. *Semin Liver Dis*. 2008;28(3):259-69. <http://dx.doi.org/10.1055/s-0028-1085094>. PMID:18814079.
4. Mahmoud AE, Mendoza A, Meshikhes AN, et al. Clinical spectrum, investigations and treatment of Budd-Chiari syndrome. *QJM*. 1996;89(1):37-43. <http://dx.doi.org/10.1093/oxfordjournals.qjmed.a030135>. PMID:8730341.
5. Darwish Murad S, Valla DC, de Groen PC, et al. Determinants of survival and the effect of portosystemic shunting in patients with Budd-Chiari syndrome. *Hepatology*. 2004;39(2):500-8. <http://dx.doi.org/10.1002/hep.20064>. PMID:14768004.
6. Dancygier H. Hepatic veins. In: Dancygier H, editor. *Clinical hepatology: principles and practice of hepatobiliary diseases*. Berlin, Heidelberg: Springer-Verlag; 2010. v. 2. p. 641-47. http://dx.doi.org/10.1007/978-3-642-04519-6_5.

7. Chung RT, Iafrate AJ, Amrein PC, Sahani DV, Misdraji J. Case records of the Massachusetts General Hospital. Case 15-2006. A 46-year-old woman with sudden onset of abdominal distention. *N Engl J Med*. 2006;354(20):2166-75. <http://dx.doi.org/10.1056/NEJMcpc069006>. PMID:16707754.
8. MacNicholas R, Olliff S, Elias E, Tripathi D. An update on the diagnosis and management of Budd-Chiari syndrome. *Expert Rev Gastroenterol Hepatol*. 2012;6(6):731-44. <http://dx.doi.org/10.1586/egh.12.56>. PMID:23237258.
9. Valla DC. Hepatic vein thrombosis (Budd-Chiari syndrome). *Semin Liver Dis*. 2002;22(1):5-14. <http://dx.doi.org/10.1055/s-2002-23202>. PMID:11928075.
10. Horton JD, San Miguel FL, Membreno F, et al. Budd-Chiari syndrome: illustrated review of current management. *Liver Int*. 2008;28(4):455-66. <http://dx.doi.org/10.1111/j.1478-3231.2008.01684.x>. PMID:18339072.
11. Bolondi L, Gaiani S, Li Bassi S, et al. Diagnosis of Budd-Chiari syndrome by pulsed Doppler ultrasound. *Gastroenterology*. 1991;100(5 Pt 1):1324-31. PMID:2013376.
12. Copelan A, Remer EM, Sands M, Nghiem H, Kapoor B. Diagnosis and management of Budd Chiari syndrome: an update. *Cardiovasc Intervent Radiol*. 2015;38(1):1-12. <http://dx.doi.org/10.1007/s00270-014-0919-9>. PMID:24923240.
13. Faraoun SA, Boudjella ME, Debzi N, et al. Budd-Chiari syndrome: a prospective analysis of hepatic vein obstruction on ultrasonography, multidetector-row computed tomography and MR imaging. *Abdom Imaging*. 2015. [Epub ahead of print]. <http://dx.doi.org/10.1007/s00261-015-0380-5>. PMID:25687630.
14. Kim H, Nahm JH, Park YN. Budd-Chiari syndrome with multiple large regenerative nodules. *Clin Mol Hepatol*. 2015;21(1):89-94. <http://dx.doi.org/10.3350/cmh.2015.21.1.89>. PMID:25834807.
15. Pavri TM, Herbst A, Reddy R, Forde KA. Budd-Chiari syndrome: a single-center experience. *World J Gastroenterol*. 2014;20(43):16236-44. PMID:25473178.
16. Nishida N, Iwamura S, Ida H, et al. Clinical and histological features of different types of Budd-Chiari syndrome: a comparison of 4 cases. *Dig Dis*. 2013;31(5-6):408-14. <http://dx.doi.org/10.1159/000355237>. PMID:24281013.
17. Khuroo MS, Al-Suhabani H, Al-Sebayel M, et al. Budd-Chiari syndrome: long-term effect on outcome with transjugular intrahepatic portosystemic shunt. *J Gastroenterol Hepatol*. 2005;20(10):1494-502. <http://dx.doi.org/10.1111/j.1440-1746.2005.03878.x>. PMID:16174064.
18. De BK, Sen S, Biswas PK, et al. Occurrence of hepatopulmonary syndrome in Budd-Chiari syndrome and the role of venous decompression. *Gastroenterology*. 2002;122(4):897-903. <http://dx.doi.org/10.1053/gast.2002.32419>. PMID:11910341.

Conflict of interest: None

Submitted on: May 14, 2015

Accepted on: May 28, 2015

Correspondence

Camila Kruschewsky Falcão

Hospital das Clínicas - Faculdade de Medicina - Universidade de São Paulo

Rua Alves Guimarães, 434 – Pinheiros - São Paulo/SP – Brazil

CEP: 05410-000

Phone: +55 (71) 8121-9754

E-mail: camilakf@outlook.com